



HAL
open science

Anatomy and biomechanics of healthy and arthritic trapeziometacarpal joints

Christian Fontaine, P. D'agostino, Catherine Maes-Clavier, M. Boutan,
Nadine Sturbois-Nachef

► **To cite this version:**

Christian Fontaine, P. D'agostino, Catherine Maes-Clavier, M. Boutan, Nadine Sturbois-Nachef. Anatomy and biomechanics of healthy and arthritic trapeziometacarpal joints. *Hand Surgery and Rehabilitation*, 2021, 40, pp.3-14. 10.1016/j.hansur.2020.09.014 . hal-03710392

HAL Id: hal-03710392

<https://uphf.hal.science/hal-03710392>

Submitted on 22 Aug 2023

HAL is a multi-disciplinary open access archive for the deposit and dissemination of scientific research documents, whether they are published or not. The documents may come from teaching and research institutions in France or abroad, or from public or private research centers.

L'archive ouverte pluridisciplinaire **HAL**, est destinée au dépôt et à la diffusion de documents scientifiques de niveau recherche, publiés ou non, émanant des établissements d'enseignement et de recherche français ou étrangers, des laboratoires publics ou privés.



Distributed under a Creative Commons Attribution - NonCommercial 4.0 International License

Anatomy and biomechanics of healthy and arthritic CMC1 joint

Anatomie et biomécanique de l'articulation trapézo-métacarpienne saine et arthrosique

C. Fontaine^{1,2,3}, P. D'Agostino⁴, C. Maes-Clavier⁵, M. Boutan⁶, N. Sturbois-Nachef³

1 : Laboratoire d'anatomie et organogenèse, Faculté de Médecine Henri Warembourg, Université de Lille, Rue Michel Polonovski, 59045 Lille cedex, France

2 : Laboratoire d'Automatique, de Mécanique et d'informatique industrielle et Humaine LAMIH, Université de Valenciennes et du Hainaut-Cambrésis, Le Mont Houy, 59313 Valenciennes cedex, France

3 : Clinique de Traumatologie-Orthopédie, Hôpital Roger Salengro, Rue du Professeur Emile Laine, CHRU de Lille, 59037 Lille cedex, France

4 : Clinique de la Main, Bruxelles et Brabant-Wallon, Avenue Louise 284, 1050 Bruxelles, Belgique

5 : Service de chirurgie orthopédique et traumatologique, CHU Amiens-Picardie, Site sud Route départementale 408, 80054 Amiens cedex 1, France

6 : Résidence Dryades, Bâtiment A1, 1, rue du 11 novembre, 40990 Saint-Paul-les-Dax, France

Auteur correspondant :

Pr Christian Fontaine

Laboratoire d'anatomie et organogenèse – Faculté de Médecine Henri Warembourg – Université de Lille – Place de Verdun – 59045 Lille cedex – France

Tel : 06 62 26 33 83

Fax : 03 20 44 67 71

christian.fontaine@chru-lille.fr

Conflits d'intérêts :

C. Fontaine : Essais cliniques : en qualité de co-investigateur, expérimentateur non principal, collaborateur à l'étude pour Hospital & Healthcare Consulting. Conférences : invitations en qualité d'intervenant pour Allergan, IPSEN et MERZ. Il n'a pas d'autres liens d'intérêt.

Les autres auteurs n'ont pas de conflit d'intérêt à déclarer.

1 **Anatomy and biomechanics of healthy and arthritic trapeziometacarpal joints**

2

3 **Anatomie et biomécanique de l'articulation trapézo-métacarpienne saine et**
4 **arthrosique**

5

6 **Abstract**

7 Understanding the biomechanics of the trapeziometacarpal (TMC) or first carpometacarpal
8 (CMC1) joint, the pathophysiology of basal thumb arthritis, the design and performance of
9 surgical procedures require a solid anatomical basis. This review of literature summarizes
10 the most recent data on the descriptive, functional, and comparative anatomy of healthy and
11 arthritic TMC joints.

12

13 **Résumé**

14 La compréhension de la biomécanique de l'articulation trapézo-métacarpienne (ATMC), de la
15 physiopathologie de la rhizarthrose, la conception et la réalisation des gestes chirurgicaux
16 nécessitent de solides bases anatomiques. Cette revue de la littérature synthétise les
17 données les plus récentes concernant l'anatomie descriptive, fonctionnelle et comparée de
18 l'ATMC saine et arthrosique.

19

20 *Keywords:* Anatomy; Biomechanics; Trapeziometacarpal joint; 1st carpometacarpal joint;
21 Osteoarthritis

22

23 *Mots-clés:* Anatomie ; Biomécanique ; Articulation trapézo-métacarpienne ; 1^{ère} articulation
24 carpo-métacarpienne ; Rhizarthrose

25

26 **1. Introduction**

27 The trapeziometacarpal (TMC) or first carpometacarpal (CMC1) or basal thumb joint is
28 crucial to providing the thumb with its large range of motion. This is particularly true when an
29 arthrodesis has been performed at the more distal joints to address inflammatory,
30 degenerative, or post-traumatic conditions. It is affected in basal joint arthritis for reasons that
31 are still not well understood. Knowledge of its anatomy and biomechanics is essential to
32 understanding the pathophysiology of basal joint arthritis and to designing surgical
33 procedures.

34 The following topics will be reviewed:

- 35 - the thumb's role in the hand and thumb movements
- 36 - the normal TMC joint
- 37 - the arthritic TMC joint
- 38 - the operated TMC joint
- 39 - the TMC joint in an evolutionary context.

40

41 **2. The thumb: its role in the hand and its movements**

42 The thumb is the shortest of our digits. Its skeleton consists of two carpal bones (scaphoid
43 and trapezium), the first metacarpal and only two phalanges (proximal and distal). These
44 bones are articulated by four joints: 1) scaphotrapezium, anterolateral portion of the
45 scaphotrapezotrapezoid (STT) joint, 2) TMC, 3) metacarpophalangeal (MCP) and 4)
46 interphalangeal (IP).

47 To be able to be opposed to the other fingers, while also being able to flatten the
48 hand on a hard surface, the thumb is not located in the same plane as the other fingers. At
49 rest, it makes an angle of nearly 45° open laterally in the frontal plane and of nearly 30° open
50 anteriorly in the sagittal plane with the longitudinal axis of the forearm prolonged by the axis
51 of the middle finger.

52 Before we look at the ligaments and muscles, it is important to define the basic
53 movements the thumb can make. We will adopt the terms typically used in the anatomical

54 and clinical context [1], although engineers who perform biomechanical studies use Euler
55 angles, which are harder for clinicians to grasp [2].

56 The movements of *antepulsion* and *retropulsion* occur at the TMC joint in the sagittal
57 plane. They are defined relative to the plane of the palm, considered as the frontal reference
58 plane. Antepulsion (or anteposition) bring the thumb in front of the plane of the palm.
59 Retropulsion (or retroposition) brings the thumb behind this plane. These movements occur
60 around an axis passing through the trapezium [3], which is angled anteriorly, laterally, and
61 proximally (Fig. 1). Their mean amplitude of 53° ranges between 50° and 90° [4].

62 The movements of *abduction* and *adduction* occur at the TMC joint in the frontal
63 plane (that of the palm). Abduction spreads the thumb away from the second metacarpal
64 while adduction brings it closer. These movements occur around an axis passing through the
65 base of the first metacarpal [3], which is angled anteriorly, medially, and slightly distally (Fig.
66 1). Their mean amplitude has been measured at 42° [4], 51° [5], and up to 76° [6].

67 The movements of *flexion* and *extension* occur in the thumb's longitudinal plane,
68 angled about 45° relative to the frontal plane and 30° relative to the sagittal plane; it involves
69 the thumb's three main joints. Flexion brings the tip of the thumb towards the palm, while
70 extension moves it away. Their mean amplitude is between 40 and 45 degrees: 41° [5], 43°
71 [6].

72 The movements of *pronation* and *supination* occur along the longitudinal axis of the
73 bones. Relative to the plane of the thumb's tip, we can distinguish between pronation, which
74 turns the tip so that it opposes itself to the tips of the other fingers (internal rotation) and
75 supination, which turns the thumb's tip in the other direction (external rotation). These
76 movements are a continuation of those of the forearm. Their mean amplitude is between 15
77 and 25 degrees: 17° [4], 21° [5], 23° [6].

78 Next, *opposition* is the ability to bring the thumb's tip into contact with the tip of one of
79 the other four fingers to create a pinch grip (from the Latin *pollex, pollicis*, which means
80 thumb). Opposition has four elements: antepulsion and adduction, which mainly occur in the
81 TMC joint; flexion, which mainly occurs in the MCP joint; pronation whose amplitude

82 decreases from the base of the thumb to its distal tip (60° in the TMC, 23° in the MCP, 7° in
83 the IP [7]). During a clinical examination, opposition is evaluated with the Kapandji score [8].
84 Now, *counteropposition* is the reverse movement; it can also be evaluated with the Kapandji
85 score [8].

86 Next is *apoposition* (apo = spread way) has been described as the position in which
87 the TMC is completely abducted and supinated, while one or both of the thumb's distal
88 articulations are flexed. Apoposition is the thumb position required for writing [9].

89 All these basic movements are combined to achieve *circumduction*: flexion-extension
90 of 27°, adduction-abduction of 37° and pronation-supination of 10° [10]. It occurs around a
91 middle circumduction center located at the center of the trapezial articular surface [11]. It
92 allows the tip of the thumb to move in space by an average of 103 mm in abduction-
93 adduction and 131 mm in flexion-extension; however, in common gestures, only two-thirds of
94 this range is used (67 and 73 mm, respectively) [12].

95 The amplitude of all these movements varies greatly in the general population and is
96 influenced by age and sex [13]. It is similar in the dominant or non-dominant hand, in women
97 or men [14].

98 The "reference position" of the first metacarpal, in which the reference axes of the
99 trapezium and first metacarpal are aligned, entails 48° of antepulsion, 38° of abduction and
100 80° of pronation relative to the axis of the third metacarpal [4].

101

102 **3. The normal trapeziometacarpal joint**

103 3.1. Bones

104 The trapezium has six faces (Fig. 2):

- 105 - the palmar face has a groove for the flexor carpi radialis (FCR) tendon, which is
106 delimited anteriorly and laterally by the tubercle of trapezium
- 107 - the dorsal face has a tubercle on which the dorsal ligaments insert
- 108 - the proximal face articulates with the distal pole of the scaphoid

- 109 - the distal face articulates with the base of the first metacarpal; its slope in the
110 frontal plane can be measured relative to the axis of the second metacarpal; this
111 is the “dévers” or slope angle [15]
- 112 - the rougher lateral face is the site where the muscles of the thenar compartment
113 insert
- 114 - the medial face is divided into two distinct articular surfaces, one for the trapezoid
115 proximally and one for the second metacarpal distally [16].

116 The first metacarpal is the shortest of all the metacarpals. A cross-section of its canal
117 reveals a trapezoidal medial boundary and a triangular lateral boundary. The design of
118 metacarpal stems for TMC prostheses must take this into account.

119

120 3.2. Joints

121 The TMC is a saddle joint (or articulation by reciprocal reception), which opposes the distal
122 surface of the trapezium to the base of the first metacarpal. Nevertheless, few joint
123 replacement prostheses have been able to reproduce this dual saddle configuration, thus
124 most function as a ball-and-socket joint.

125

126 3.2.1. Articular surfaces

127 The trapezium has a concave surface from front to back and a convex one from inside to
128 outside. Its ridge guides flexion-extension movements. It is curved, not straight (like a road
129 going over a col [1] or like the vertebral column of a scoliotic horse). For this reason,
130 pronation always occurs with some flexion, while supination always occurs with some
131 extension.

132 The articular surface of the first metacarpal is larger than that of the trapezium,
133 convex from front to back and concave from inside to outside. Its ridge guides the
134 antepulsion and retropulsion movements. In front, it terminates as a bone beak, which gave
135 rise to the name “beak ligament”. The magnitude of the slope is not something that we
136 currently measure, but it contributes to poor outcomes after arthroplasty [17].

137 These two surfaces are not fully congruent; thus, it is not possible to characterize
138 them by two unique radiuses of curvature and by an angle between two asymptotes [18].

139

140 *3.2.2. Capsule and ligaments*

141 These soft tissue elements are responsible for the passive stability of the TMC joint. Several
142 descriptions of the ligaments around the TMC joint exist. Although it has some inaccuracies,
143 the most used one is by Bettinger et al. [19,20]. Among the 16 ligaments, the main ones are
144 (Fig. 3):

- 145 - The anterior oblique ligament (AOL) has two parts, a superficial one (sAOL) and a
146 deep one (dAOL); the deep part is intra-articular and is often referred to as the
147 "beak ligament". This ligament is taut in abduction, extension, and pronation –
148 which it limits – while it is relaxed when the thumb is in retropulsion. Its thickness
149 measured by ultrasonography varies between its metacarpal insertion (0.7 mm),
150 its middle portion (0.98 mm) and its trapezial insertion (0.65 mm). Its static length
151 actually differs between the dominant hand (10.6 mm) and the non-dominant hand
152 (9.6 mm) [21]. Measurements taken on MRI images are less precise (thickness
153 typically less than 2.2 mm) [22].
- 154 - The intermetacarpal ligament (IML) has a "Y" configuration. The two arms of the Y
155 insert on the base of the second metacarpal while its common trunk inserts on the
156 first metacarpal: the dorsal intermetacarpal ligament (DIML or dorsal first MC
157 ulnar base-second MC radial base intermetacarpal ligament [23]) and the volar
158 intermetacarpal ligament (VIML or volar first MC ulnar base-second MC radial
159 base intermetacarpal ligament [23]). It is taut in abduction, which it constrains [9].
160 Its thickness on MRI images is 3 mm (2.9–3.1 mm) [22]. This ligament is
161 reconstructed during trapeziectomy procedures to prevent proximal migration of
162 the first metacarpal.
- 163 - The dorsoradial ligament (DRL) extends between the dorsal tubercle of the
164 trapezium and the base of the first metacarpal. It is taut in abduction and flexion,

165 relaxed in antepulsion and opposition [24]; it constrains abduction. It is an
166 important stabilizer of the TMC joint because it counters the forces directed
167 dorsally and it is rich in proprioceptors. Based on MRI, its thickness is 1.2–1.4 mm
168 [22].

- 169 - The posterior oblique ligament (POL) is taut in extension and relaxed in
170 retropulsion, while it constrains supination.
- 171 - The ulnar collateral ligament (UCL) has also been called the medial collateral
172 ligament by Kuhlmann and Guérin-Surville [25]. It inserts on the medial tubercle of
173 the metacarpal, near the distal center of rotation, but further away from the
174 proximal center of rotation. It is more superficial and more ulnar than the AOL.
175 The movements made around the distal center do not involve any pronation-
176 supination, while the movements occurring around the proximal center are
177 necessarily accompanied by pronation or supination [25].

178 The stabilizing components of the trapezium can be added to this:

- 179 - The volar and dorsal **trapezio**-trapezoidal ligaments, the ligaments spanning
180 between the trapezium and second metacarpal, volar and dorsal (DT-IITM), and
181 the ligament spanning between the trapezium and third metacarpal (TIII-MC)
182 appear to function as stays to combat the moment arms acting on the trapezium
183 from the first metacarpal. In this complex, the TIII-MC ligament appears to be the
184 most important stabilizer of the trapezium [26].
- 185 - Added to this are the palmar scaphotrapezial ligament, radial scaphotrapezial
186 ligament and the trapezoidal-capitate ligament.

187 In addition to these main ligaments, Ladd et al. identified a central dorsal ligament
188 [27]. Kuhlmann identified an anteromedial ligament, part of the posteromedial ligament
189 complex, named the retinaculometacarpal ligament due to its proximal insertion, which plays
190 a key role in the suspension and anchoring of the base of the first metacarpal. It induces
191 slight translation of the metacarpal along the concave articular surface of the trapezium
192 during lateral pinch grips and pronation-supination of 90° [28].

193 The appearance and location of the dorsal ligaments (DTM, POL, DCL and DRL) are
194 consistent during arthroscopy, but those of the palmar ligaments (sAOL, dAOL and UCL)
195 vary greatly: the sAOL resembles a thin veil of membranous tissue that is draped in a
196 variable manner on the anterior portion of the joint capsule. What is known as the AOL and
197 UCL appears to correspond solely to a thicker portion of this veil around the volar beak,
198 although these ligaments cannot always be identified during macroscopic dissection [29].

199 Initially, several authors [19,30,31] claimed that the AOL, with its two layers
200 (especially the dAOL) was the thicker and mechanically more important one, although it is
201 located on the same side as the powerful thenar muscles and consider it to be the main
202 stabilizer of the TMC joint. All these authors believe that the IML, UCL and POL are only
203 secondary stabilizers, which fuse to form an assemblage nucleus at the base of the first
204 metacarpal.

205 According to Imaeda et al., the DRL does not appear to play either a primary or
206 secondary role in stabilizing the thumb [11,32]. But many subsequent studies
207 [27,33,34,35,36,37,38,39,40,41] showed that the DRL was in fact shorter, thicker, less
208 extendible, stiffer, and richer in mechanoreceptors than the AOL. Thus, it appears to be the
209 main obstacle to dorsoradial subluxation. When it is transected in experimental studies, it
210 causes the most amount of dorsoradial subluxation of the first metacarpal [35,42].

211 Similarly, in histology studies, the dorsal ligaments are significantly thicker and more
212 robust than the palmar ligaments, with more cells and more sensory innervation than the
213 AOL. The AOL is a thin structure that has the histological appearance of a low cellularity
214 capsular tissue instead of a true ligament; its location and insertions vary [27].

215 The dorsal ligaments (DRL, DCL and POL) have significantly more nerve endings
216 than the palmar ligaments (AOL and UCL) [38,43]. Most of the nerve endings are near the
217 bone insertions. Ruffini corpuscles are the predominant type of mechanoreceptor, with a
218 higher density in the metacarpal portion of each ligament. Along with their biomechanical
219 contribution to TMC stability, their presence suggests that these ligaments have a
220 proprioceptive function [38].

221 According to Comtet et al, the intermetacarpal ligaments (26%) and the AOL (39%)
222 are subjected to the highest loads during thumb movements in the posteromedial and
223 posterolateral directions, while the DRL and POL are subjected to lower loads (12%) in the
224 other directions (anteromedial, medial, anterolateral, and maximum anteposition) [33].
225

226 *3.2.3. Adjacent joints*

227 Proximally, the STT joint is a planar articulation. It contributes to the thumb's mobility, as
228 shown by D'Agostino et al., in flexion, adduction and especially in rotation [44,45].

229 Distally, the MCP joint is theoretically an ellipsoid (condylar) joint with two degrees of
230 freedom: flexion-extension and radial and ulnar deviation. However, the two sesamoid bones
231 and two powerful collateral ligaments limit its mobility in ulnar and radial deviation to favor
232 stability. Consequently, the thumb MCP joint functions like a joint with a single degree of
233 freedom. The metacarpal head is asymmetric: of its two palmar tubercles, the radial one is
234 the largest; in 25-30° of flexion, it articulates with a hollow in the base of the proximal
235 phalanx; when the UCL is under tension, this contributes to limiting abduction and external
236 rotation [9]. The mean flexion amplitude is 56° [46] or 77° [47], depending on the shape of
237 the metacarpal head: up to 70° flexion can occur if the head is round, but less than 40° if the
238 head is flat [47]. The functional mobility ranges from 10° flexion deformity to 2° flexion
239 according to Hume et al. [46] or 7.5° of flexion deformity to 5° flexion according to Murai et al.
240 [48].

241 More distally, the IP joint is a hinge joint with a single degree of freedom associated
242 with automatic rotation: flexion-pronation to one side and extension-supination to the other.
243 Here again, the head of the phalanx is asymmetric: its radial lip is larger than its ulnar one;
244 when the UCL is under tension, this contributes to limiting abduction [9]. The IP is used
245 during all gestures of day-to-day living [49].

246

247 *3.3. Muscles*

248 The muscles are responsible for active stabilization of the TMC joint. The thumb appears
249 imbalanced since there are four extrinsic muscles (including three on the dorsal side) and
250 five intrinsic muscles (all located on the palmar side).

251 The following are the long or extrinsic muscles:

- 252 - The abductor pollicis longus (APL) is a complex muscle with deep and superficial
253 parts [50]. The deep part has the larger muscle body and inserts around the TMC
254 joint. The superficial part and every component of the deep part receive a different
255 nerve branch than the deep branch of the radial nerve destined to the APL. It has
256 a single tendon in only 5% of cases [51]. Most often it is formed of two to six
257 tendons distributed into two groups (Fig. 4): a lateral one ending on the base of
258 the first metacarpal and a medial one inserting either on the base of the first
259 metacarpal (80% on anterolateral face and 20% on lateral face), on the trapezium
260 (70-80%), the APB (60%), the thenar fascia (40–42%), the TMC joint capsule
261 (30%) or the opponens pollicis (20%) [51,52]. The capsular insertions may
262 reinforce certain ligaments [53]. It is mainly an abductor while also being an
263 extensor of the TMC joint [54]; the superficial portion is said to work with the
264 extensor pollicis brevis (EPB). Several anatomical studies have found no
265 correlation between the severity of osteoarthritis and the types of distal APL
266 insertions [51,55,56,57].
- 267 - The EPB is mainly an extensor, but also a weak abductor of the TMC joint
268 [54,58,59,60].
- 269 - The extensor pollicis longus (EPL) is both an extensor and an adductor of the
270 TMC joint [54] acting simultaneously and in a coordinated manner on the IP and
271 MCP joints [61].
- 272 - The flexor pollicis longus (FPL) is a pure flexor [53], acting simultaneously and in
273 a coordinated manner on the IP and MCP joints [61].

274 The APL, EPB and EPL have a combined extension and supination action on the TMC joint
275 [61].

276 The short or intrinsic muscles are arranged in two layers, differentiated by their
277 position relative to the tendon of the FPL and their innervation:

278 - The superficial thenar muscles are innervated by the recurrent branch of the
279 median nerve and are located in front of the FPL tendon.

280 ○ The abductor pollicis brevis (APB) is responsible for flexion, antepulsion
281 and pronation (but not abduction, more likely adduction [54]) of the TMC
282 joint. It contracts at the same time as the APL during many thumb
283 movements, acting as a stabilizer.

284 ○ The opponens pollicis is the only muscle that terminates on the first
285 metacarpal; it is responsible for flexion, antepulsion, and pronation of the
286 TMC joint, along with abduction [54].

287 ○ The superficial head of the flexor pollicis brevis (FPB)

288 - The deep thenar muscles are innervated by the deep branch of the ulnar nerve
289 and are located behind the FPL tendon:

290 ○ The deep head of the flexor pollicis brevis (FPB)

291 ○ The adductor pollicis is responsible for adduction, retropulsion and
292 supination of the TMC joint, along with flexion [54]; it has two heads,
293 transverse and oblique.

294 - The first dorsal interosseous muscle also acts on the TMC joint; it has also been
295 called the lateral **thenar** muscle. When it contracts, it reduces the subluxation of a
296 healthy TMC joint [62]. This muscle causes the least dorsoradial translation and
297 causes the most distal translation of the metacarpal base [63]. For this reason,
298 there is an emphasis placed on this specific muscle during the rehabilitation for
299 thumb basal joint arthritis.

300 The APL and adductor pollicis form a destabilizing functional pair, responsible for the
301 abduction and dorsolateral subluxation of the first metacarpal (APL) and closure of the first
302 web, which is made worse by all the other intrinsic muscles.

303 Based on their position relative to the main axis of the TMC joint, we can differentiate:

- 304 - antepulsion muscles: FPL, APB, opponens pollicis and superficial head of the
- 305 FPB
- 306 - retropulsion muscles: EPL, EPB, first dorsal interosseous
- 307 - abduction muscles: APL
- 308 - adduction muscles: adductor pollicis, deep head of FPB, first dorsal interosseous.

309 When we look at the thumb's overall movements, the FPL is the primary driver of
310 isometric flexion; the EPL and APL are the primary drivers of isometric extension, the
311 adductor pollicis and EPL are the primary drivers of isometric adduction; the APB and
312 opponens pollicis are the primary drivers of isometric abduction [64]. During pinching and
313 power gripping, the adductor pollicis and the FPL have the same electrical activity, with
314 secondary contributions from the first dorsal interosseous and EPL. During key pinch, power
315 grip and jar opening, the muscle recruitment is specific to each person but varies little from
316 one task to another. The thumb's extrinsic muscles are significantly more active than the
317 intrinsic muscles during these three tasks [65].

318 When the intrinsic muscles are absent, the action of the EPL and FPL tendons alone
319 tends to extend the TMC joint when it is not stabilized, to extend the MCP when it is
320 stabilized, and to flex the IP joint [66].

321

322 3.4. Vascularization

323 The arteries of the TMC joint come from the radial artery and its branch, the main artery of
324 the thumb. They form a vascular network around the joint, which is denser on the dorsoradial
325 side of the joint [67]. It is essential to be aware of its vascularization and to preserve it when
326 doing peritrapezial osteotomies [68].

327

328 3.5. Innervation and the basis for denervation

329 The TMC is innervated by the radial and median nerves. The branches of the median nerve
330 are more numerous and larger; they come from the palmar branch (11/15) and the recurrent
331 branch by following a retrograde arcuate path between the APB and the opponens pollicis

332 (13/15), and sometimes directly from the median nerve in the carpal tunnel (5/15). The
333 participation of the lateral cutaneous nerve of the forearm and the superficial branch of the
334 radial nerve is more modest [69]. According to Loréa, the thenar branch is divided into at
335 least two main branches, one for the opponens pollicis and the other for the APB. Very often,
336 the branch for the opponens pollicis courses over or inside its medial face to spread out on
337 the palmar face of the trapezium [70,71]. The superficial branch of the radial nerve does not
338 have an exclusive or dominating role in the TMC joint's innervation [72]. The deep branch of
339 the ulnar nerve also innervates the TMC, which could explain some of the potential failures of
340 denervation [73].

341 According to Loréa et al., two incisions are needed to transect all the articular
342 branches coming from the superficial branch of the radial nerve, the palmar cutaneous
343 branch of the median nerve, the recurrent branch of the median nerve and the lateral
344 cutaneous nerve of the forearm [69,74].

345

346 3.6. Anatomical relationships

347 The radial artery is 4 or 5 mm proximal to the dorsal arthroscopic portal, following a course
348 4–8 mm from the joint space and 8–11 mm from the EPB. Some of the sensory branches
349 coming from the dorsal branch of the radial nerve are close to the dorsal surgical approach.
350 According to Espinosa Gutiérrez et al., there is a safe zone for the dorsal arthroscopy portal
351 between the EPL and EPB [75].

352

353 3.7. Biomechanics

354 3.7.1. Stability

355 The contact area is the greatest during palmar abduction and the least in adduction [10].
356 When centered, the contact surfaces are reduced [76]. Their span is minimal, a bit less on
357 the trapezium than the base of the first metacarpal [77]. The location and breadth of the
358 contact areas vary by the type of movement done [78]:

- 359 - latero-palmar on the trapezium and lateral on the first metacarpal in opposition,
360 representing 53% of the articular surfaces [78] with a stress concentration on this
361 zone during power gripping [77]
- 362 - lateral (radial) on the trapezium and the first metacarpal in palmar abduction,
363 representing 28% of the articular surfaces [78]
- 364 - dorsal on the trapezium and the first metacarpal in radial abduction, representing
365 25% of the articular surfaces [78]
- 366 - central palmar for the trapezium and first metacarpal during circumduction, except
367 in adduction [10].

368 In the study by Ateshian et al. [79], key pinch was responsible for contact areas primarily in
369 the central, palmar, and ulnar portions of the trapezium and metacarpal. The TMC remains
370 stable during key pinch, jar grasp and jar twist, with no difference between sexes [80].

371

372 *3.7.2. Loads*

373 A famous study by Cooney and Chao [81] showed that the extrinsic and intrinsic tendons
374 supported loads of up to 10 and 30 kg, respectively, during a pinch grip, producing a 5 kg
375 load at the tip of the thumb and that tendon forces reached 50 kg during power grip. The
376 compression loads were calculated to be 3 kg at the IP joint, 5.4 kg at the MCP joint and 12
377 kg at the TMC joint during a pinch grip generating 1 kg (Fig. 5). They could reach 120 kg
378 during a power grip.

379

380 *3.7.3. Resting position*

381 At rest, the TMC has a slight subluxation dorsally (1.8–2.0 mm) and radially (2.8–3.4 mm)
382 [22].

383

384 *3.7.4. Mobility*

385 According to Zancolli et al., the TMC is shaped to allow isolated angular movements
386 but also associated angular and rotational movements of the first metacarpal. To accomplish

387 this, the geometry of the joint is compartmentalized: one section has a saddle shape (central
388 zone of the trapezial surface and metacarpal crest) where the simpler angular movements
389 occur, while another section has a spheroid shape (palmar portion of the trapezial articular
390 surface and the slopes of the metacarpal surfaces) where combined movements occur [82].

391 The two main axes of the TMC are in non-orthogonal and non-secant planes [83],
392 which differ from the anatomical reference planes and explains why complex movements do
393 not occur in the classical reference planes (frontal or sagittal) but in planes that are oblique to
394 these reference planes. The flexion-extension axis passes through the trapezium while the
395 abduction-adduction axis passes through the first metacarpal [11,84]. Thus flexion-extension
396 and abduction-adduction movements are coupled with automatic internal and external
397 rotation movements along with translation movements: internal rotation and ulnar translation
398 is coupled with flexion, implying a screw-like stabilization mechanism [44,84]. The base and
399 head of the first metacarpal shift in the same direction during flexion-extension but in
400 opposite directions during abduction-adduction [11].

401 During flexion, all the ligaments are placed under tension, except for the beak
402 ligament which becomes slack. During adduction and opposition, the POP and DIM are
403 placed under tension, while the DRL and beak ligament slacken [37].

404 Axial rotation of the TMC mainly occurs when the hand is used during a cylindrical or
405 spherical grip [49]. Axial rotation is controlled by muscles; when the joint is compressed,
406 there is not more than 3° motion [18]. During opposition, the flexion and pronation
407 movements are coupled [7].

408

409 3.8. Sex-related variations

410 Unsurprisingly, the bones in women are smaller than those in men, thus the articular
411 surfaces are also. There is no difference in the width of the TMC joint space between young
412 men and young women [24], nor any differences in joint congruency [85] or kinematics [80].
413 According to Schneider et al. [86], there is no difference in the shape of the metacarpal
414 surface between men and women. According to Ateshian et al. [87], the congruency is not as

415 good in women as it is in men: the concavity of the metacarpal surface and the convexity of
416 the trapezial surface are less pronounced in women than in men [88,89].

417

418 **4. The arthritic trapeziometacarpal joint**

419 Basal joint arthritis is attributed to TMC instability/hypermobility, which is visible on stress X-
420 ray images [90] allowing lateral translation of the metacarpal on the trapezium [30,91,92];
421 however, this was contradicted by the study of Kraus et al. [93]. Lesions identical to the ones
422 seen in osteoarthritis were simulated by transecting the beak ligament [94].

423

424 4.1. Incidence of basal joint arthritis by age and sex and combination with other types of 425 arthritis

426 In a British study, symptomatic clinical and radiological basal joint arthritis affects 2.2% of the
427 population and isolated erosive finger osteoarthritis is found in 0.5%, although these two
428 conditions are very often present at the same time [95]. In a Swedish study, basal joint
429 arthritis was the reason for consultation with a general practitioner in 1.4% of patients over
430 20 years of age (2.2% in women and 0.6% in men). The mean age at the time of consultation
431 was 68 years, although women were seen at a younger age than men by about 10 years
432 [96]. In post-menopausal women, the prevalence of isolated TMC arthritis, STT arthritis and
433 **peritrapezial** TMC+STT arthritis was 25%, 2% and 8%, respectively. Only 28% of cases of
434 isolated TMC arthritis and 55% of TMC + STT osteoarthritis were symptomatic [97]. In a
435 cadaver study with 69 specimens, severe concurrent osteoarthritis was found in the TMC
436 and STT joints of 60% of specimens. There was a correlation between the severity of the
437 TMC arthritis and that of STT arthritis. Radiographic and macroscopic changes in the STT
438 joint were visible in 39% of subjects [98]. Similarly, the presence of STT arthritis is highly
439 correlated with the presence of TMC arthritis [99].

440 In a cohort of 36 fresh cadaver TMC joints, Maes-Clavier et al. found that 17 joints
441 (71% men) were stage I (no osteoarthritis) to stage III (moderate osteoarthritis) while 19
442 joints (95% women) were stage IV (major cartilage damage) [100].

443

444 4.2. Macroscopic changes in the trapeziometacarpal joint due to basal joint arthritis

445 Unsurprisingly, basal joint arthritis leads to narrowing of the joint space [24,88], changes in
446 joint congruency [85] and loss of trapezial height.

447 The cartilage in an arthritic TMC joint is said to be thinner by 0.8 ± 0.2 mm for the
448 trapezium and 0.7 ± 0.2 mm for the metacarpal. This affects the radial sides of the
449 metacarpal initially, progressing towards the palmar sides and the dorsoradial side of the
450 trapezium, progressing towards the palmar sides [88,89].

451 Degenerative lesions are mainly observed in the zones loaded during joint
452 movements, especially opposition [100]: on the radial, palmar, and ulnar facets of the
453 trapezium [78,84,101], and the dorsal and palmar facets [84] and ulnar facet [101] of the
454 metacarpal. The arthritic changes are less severe on the dorso-ulnar portion of the trapezium
455 and the dorsal portion of the metacarpal, known to be the less-loaded regions [102]. As the
456 arthritis worsens, the concavity of the trapezium become deeper while its convexity becomes
457 flatter whereas the metacarpal's concavity flattens, and its convexity increases [103,104];
458 these changes are more apparent in women than in men [89]. This results in an increase in
459 the joint congruency, although it is less in women than in men [105]. The average ratio
460 between the dorso-palmar diameter and the transverse diameter of the metacarpal
461 articulating surface increases. Lengthening of the articular surface [100] in the dorso-palmar
462 direction is related to the presence of a palmar osteophyte.

463 The trapezium loses proximo-distal thickness (22% according to Nufer et al. [106]),
464 but as a reaction to the increased stresses, the thickness of the subchondral bone increases
465 by 50%, and the bone volume increases 42% because of an increase in the number (10%),
466 thickness (18%) and connectivity of the bone trabeculae [106,107]. These modifications are
467 more apparent in the dorsoradial part of the joint [102,108]. The women in their study with
468 confirmed osteoarthritis had a more pronounced radio-ulnar incurvation than the men with
469 osteoarthritis [108]. The wear is asymmetric, resulting in an increase in the trapezial slope:

470 42° ± 4° for hands without arthritis or with Eaton stage I or II arthritis, 50° ± 4° for hands with
471 Eaton stage III and IV arthritis [20].

472 Despite the joint space narrowing, the mean distance between the ligament insertions
473 and the metacarpal articular surface remains greater than 2 mm, except for the metacarpal
474 insertion of the DRL [100]. There are also soft tissue lesions that affect only the metacarpal
475 insertion of the beak ligament [109]: degeneration of its metacarpal insertion was observed
476 during palmar chondromalacia with complete detachment when the surfaces are eburnated
477 [110]. The mechanical properties (resistance to stretching) of the main ligaments decrease
478 [34] in a directly correlated manner with the condition of the TMC cartilage and with age.
479 Slackening of the ligaments alters the mechanical balance of the musculotendinous stays,
480 especially the APL and EPB, which may contribute to the joint deformities observed in basal
481 joint arthritis [111].

482 The centers of rotation of flexion-extension are translated more dorsally in the patient
483 group, while the centers of rotation during abduction-adduction are not altered [112,113].

484 Basal joint arthritis is also accompanied by changes in the function of the thumb's
485 intrinsic muscles [114]: loss of APB effectiveness secondary to changes in its vector, loss of
486 electrical activity and 50% loss in the cross-section area of the superficial portion of the FPB.

487

488 4.3. Ethnic variations

489 The frequency and distribution of idiopathic basal joint arthritis varies greatly among
490 different ethnic groups according to a study done on 61 Asian and 100 Caucasian cadavers
491 [110]. Among the 35 Japanese cadavers, 23 (66%) had completely normal articular surfaces,
492 5 (14%) had chondromalacia limited to the dorsal part of the articular surfaces, 2 (6%) had
493 chondromalacia in the palmar portion of the articular surfaces and five (14%) had visible
494 subchondral bone with advanced degenerative lesions. A similar distribution was found in the
495 22 Chinese cadavers. When it was present, osteoarthritis had the same features as those
496 observed in Caucasians. The concave-convex configuration of the articular surfaces was
497 flatter in Asians than in Caucasians. In the latter, only 25% had normal articular surfaces,

498 10% had dorsal chondromalacia considered as being age-related, 15% had palmar
499 chondromalacia considered as being pre-arthritic, while 50% had visible subchondral bone
500 with advanced arthritis.

501

502 4.4. Microscopic and biological changes in basal joint arthritis

503 Biochemically, the palmar articular surfaces affected by chondromalacia are
504 characterized by a loss of glycosaminoglycans, retention of collagen, and shift in the sub-
505 species of glycosaminoglycans, as evidenced by the increased chondroitin sulfate/keratan
506 sulfate ratio. This contrasts with the dorsal articular surface that biochemically resemble the
507 normal surfaces of the trapezium's articular facets for the scaphoid and trapezoid [115].

508 Histologically, the earliest changes are seen in the tangential surface layer and occur
509 in the areas of chondromalacia in the volar portion of the contact areas. Progressive
510 disruption of this superficial fibrillar layer of the articular cartilage is followed by
511 disorganization of the chondrocytes and underlying matrix. In the palmar portion where the
512 chondromalacia lesions are more advanced, we observe a loss of eosinophilic staining, free
513 cellular elements, and craters 20–30 mm in diameter resembling empty chondrocytic lacuna,
514 and an absence of any meshing of the tangential surface. In the eburnated zones where the
515 sub-chondral bone is visible, there are no cellular nor fibrillar elements. The disruption of the
516 protective layer of articular cartilage occurs in a spatial configuration corresponding to the
517 contact zones where selective decomposition of the proteoglycan matrix has been observed
518 [115]. The water content increases, the proteoglycan content decreases and the collagen
519 content relative to dry weight does not change. Concurrently, the compression stiffness and
520 the permeability decrease, contrary to what has been observed in the hip and knee [116].

521 The collagen fibers of the beak ligament are disorganized at their metacarpal
522 insertion. The normal fibrocartilage insertion zone is often not identifiable on the metacarpal
523 side, and in cases of more advanced arthritis, a synovial recess appears across from the
524 palmar beak of the metacarpal. The trapezial insertion of the beak ligament has no
525 degenerative alterations. Severe cartilage lesions are associated with progressive and

526 selective degeneration of the collagen network of the beak ligament at its metacarpal
527 insertion [109].

528 The decrease in ligament strength may be due to relaxin, a peptide hormone that
529 relaxes ligaments before a woman gives birth, by the intermediary of remodeling of the
530 extracellular matrix via the regulation of matrix metalloproteases acting on the relaxin/insulin-
531 like family peptide receptors 1 (RXFP-1). These are receptors for circulating relaxin, which
532 are present in ligaments, cartilage, and the synovial membrane, and in higher concentrations
533 in basal joint arthritis [117]. The DRL preserves a dense collagen organization, evidence of its
534 effectiveness, while the AOL is made of disorganized connective tissue that is low in collagen
535 and low in mechanoreceptors [42].

536

537 4.5. Consequences of anatomical lesions on function

538 Basal joint arthritis is accompanied by a reduction in TMC mobility. Stage II/III basal joint
539 arthritis restricts mobility in abduction-adduction (38° in control subjects, 26° in basal joint
540 arthritis) without restricting flexion-extension or pronation-supination. It also reduces MCP
541 mobility in abduction-adduction by 48% (32° in control subjects, 16° in basal joint arthritis)
542 and in pronation-supination by 42% (34° in control subjects, 20° in basal joint arthritis) [14]. In
543 stages III and IV, relative to a healthy population, the mobility was reduced by 14° in flexion-
544 extension (mainly on the extension side), by 26° in abduction-adduction (mainly on the
545 abduction arc), and by 13° in pronation-supination [118]. This TMC stiffness generates
546 compensatory mobility of the trapezium in abduction [113] and requires greater force
547 generation by the muscles and tendons to move it, especially the FPL and EPL, which may
548 explain the difference observed between passive and active mobility [119].

549 Early basal joint arthritis is accompanied by reduced strength in pinch grips, more
550 apparent in key pinch than in tip-to-tip or tripod pinch [120], but also in cylindrical grips [121],
551 in thumb abduction and index finger extension [122]. This measurable strength loss is
552 correlated with the clinical impact (DASH score), especially that of tip-to-tip pinch [123] and

553 can thus serve as an objective evaluation of the functional impact. In the presence of arthritis
554 in other fingers, the strength loss is specifically related to the condition of the thumb [124].

555 During three functional isometric tasks (gripping a key, holding a jar, and opening a
556 jar) in 76 patients with early basal joint arthritis, the TMC was more unstable during key pinch
557 than during the other two tasks. Sex, age, and early arthritis had no effect on TMC instability,
558 suggesting that instability during these three tasks does not predispose one to arthritis [125].

559

560 4.6. Potential for spontaneous healing

561 Lovati et al. found better chondrogenic potential in femoral chondrocytes than in trapezial
562 ones. They concluded that the trapezium had a lower regenerative capacity than the femoral
563 head [126].

564

565 4.7. Consequences of thumb basal joint arthritis on the MCP joint

566 As the adductus of the first metacarpal worsens, the MCP joint develops hyperextension that
567 allows large objects to be manipulated despite the closure of the first web. This
568 hyperextension appears more likely to develop when the metacarpal head is rounded (as
569 opposed to flat) and the first metacarpal is short, whether congenital or related to basal joint
570 arthritis (joint narrowing, trapezium collapse, subluxation, disappearance of the palmar beak
571 after AOL release) [127]. Hypermobility of the MCP may play a causal role in the
572 development of primary basal joint arthritis by concentrating the loads on the palmar part of
573 the joint, since MCP flexion unloads the most palmar part of the TMC articular surfaces, no
574 matter the severity of the basal joint arthritis [128].

575

576 **5. The operated trapeziometacarpal joint**

577 5.1. Trapeziectomy

578 According to Goubier et al., after trapeziectomy with ligament reconstruction, the TMC
579 motion is 50° during flexion-extension, 47° during abduction-adduction and 11° during axial
580 rotation. There is no significant difference with the motion of healthy joints, except for

581 circumduction that is reduced after surgery [5]. Koff et al. compared total trapeziectomy with
582 and without LRTI, the Weilby arthroplasty and the Thomson arthroplasty. Motion was better
583 after the Thomson arthroplasty and after LRTI, while trapeziectomy with LRTI yield results
584 that were the closest to those of an intact thumb [129].

585

586 5.2. Arthroplasty with a prosthesis

587 Most of the prostheses available are spheroid, with three degrees of freedom, not saddle-
588 shaped with two degrees of freedom. Under these conditions, the dislocating forces are 12
589 times greater [130].

590 This highlights how important the soft tissues are to stabilize non-retaining implants.
591 Stabilization of spheroid implants is essentially passive and relies on 1) minimal bone cuts
592 and the preservation or reconstruction of the main ligaments, 2) larger bone cuts and
593 tensioning of periarticular soft tissues, 3) use of retaining or dual mobility implants. Dynamic
594 muscular stabilization participates in passive stability; it appears to be the only mechanism to
595 control pronation and supination.

596 These days, the metacarpal stem corresponds to the shape of the medullary canal.
597 The orientation of the cup in the trapezium is more challenging. Duerinckx and Caekebeke
598 have suggested that the cup must be placed parallel to the trapezium's proximal articular
599 surface (the one that articulates with the scaphoid) and that it should be combined with a
600 metacarpal neck having 7° offset, both to optimize mobility and to minimize the risks of
601 postoperative complications [131].

602 Nevertheless, the prosthetic joint does not exactly reproduce the kinematics of the
603 healthy TMC joint [112].

604

605 **6. The trapeziometacarpal joint in an evolutionary context**

606 The saddle shape of the TMC joint is not specific to modern Man, as it has also been found
607 in hominin fossils [132]. A study of the radius of curvature of the articular surfaces confirms
608 that Man (Homo) derives from large African apes (Gorilla, Pan), from the Australopithecus

609 afarensis and from the Neandertal man, with progressive flattening. The orang-outang
610 (Pongo) lies between Man and African apes. The baboon (Papio) has surfaces that are even
611 flatter than those of Man, which are cylindrical [133]. The TMC of Man has the same mobility
612 as those of **the chimpanzee** in all movements, including coupled movements, except for
613 extension which is greater in Man [134] and the muscular couples being greater due to
614 longer moment arms [135]. The other notable feature of the thumb's evolution is widening of
615 the distal phalanx [136].

616 **7. Conclusion**

617 Knowledge of descriptive, functional, and comparative anatomy is essential to the
618 understanding of the causes and consequences of basal joint arthritis, while knowledge of
619 vascularization, innervation, and relationships of the TMC joint are needed for its surgical
620 treatment.

621 **References**

622

- 623 1. Kapandji AI. Physiologie articulaire. Tome 1: membre supérieur (6^{ème} éd.). Paris ;
624 Maloine: 2005.
- 625 2. Dumas R, Cheze L, Fayet M, Rumelhart C, Comtet JJ. [How to define the joint
626 movements unambiguously: proposal of standardization for the trapeziometacarpal
627 joint]. Chir Main 2008;27:195-201.
- 628 3. Hollister A, Buford WL, Myers LM, Giurintano DJ, Novick A. The axes of rotation of
629 the thumb carpometacarpal joint. J Orthop Res 1992;10:454-60.
- 630 4. Cooney WP 3rd, Lucca MJ, Chao EY, Linscheid RL. The kinesiology of the
631 thumb trapeziometacarpal joint. J Bone Joint Surg Am 1981;63:1371-81.
- 632 5. Goubier JN, Devun L, Mitton D, Lavaste F. In vivo kinematics of the first
633 carpometacarpal joint after trapeziectomy. Chir Main 2011;30:97-101.
- 634 6. Chang LY, Pollard NS. Method for determining kinematic parameters of the in vivo
635 thumb carpometacarpal joint. IEEE Trans Biomed Eng 2008;55:1897-906.
- 636 7. Li ZM, Tang J. Coordination of thumb joints during opposition. J
637 Biomech 2007;40:502-10.
- 638 8. Kapandji A. Clinical test of apposition and counter-apposition of the thumb. Ann Chir
639 Main 1986;5:67-73.
- 640 9. Bojsen-Moller F. Osteoligamentous guidance of the movements of the human thumb.
641 Am J Anat 1976;147:71-80.
- 642 10. Goto A, Leng S, Sugamoto K, Cooney WP 3rd, Kakar S, Zhao K. In vivo pilot study
643 evaluating the thumb carpometacarpal joint during circumduction. Clin Orthop Relat
644 Res 2014;472:1106-13.
- 645 11. Imaeda T, Niebur G, An KN, Cooney WP 3rd. Kinematics of the trapeziometacarpal
646 joint after sectioning of ligaments. J Orthop Res 1994;12:205-10.
- 647 12. Tang J, Zhang X, Li ZM. Operational and maximal workspace of the thumb.
648 Ergonomics 2008;51:1109-18.

- 649 13. Kuo LC, Cooney WP 3rd, An KN, Lai KY, Wang SM, Su FC. Effects of age and
650 gender on the movement workspace of the trapeziometacarpal joint. Proc Inst Mech
651 Eng H 2009;223:133-42.
- 652 14. Hamann N, Heidemann J, Heinrich K, Wu H, Bleuel J, Gonska C, Brüggemann GP.
653 Effect of carpometacarpal joint osteoarthritis, sex, and handedness on thumb in vivo
654 kinematics. J Hand Surg Am 2014;39:2161-7.
- 655 15. Kapandji AI, Moatti E, Raab C. La radiographie spécifique de l'articulation
656 trapézométacarpienne. Sa technique, son intérêt. Ann Chir Main 1980;34:719-26.
- 657 16. Humes D, Jähnich H, Rehm A, Compson JP. The osteology of the trapezium J Hand
658 Surg Br 2004;29:42-5.
- 659 17. Tonogai I, Hamada Y, Hibino N. Evaluation of the first metacarpal proximal facet
660 inclination as a prognostic predictor following arthroplasty for osteoarthritis of the
661 thumb carpometacarpal joint. Hand Surg 2013;18:69-72.
- 662 18. Dathe H, Dumont C, Perplies R, Fanghänel J, Kubein-Meesenburg D, Nägerl
663 H, Wachowski MM. The thumb carpometacarpal joint: curvature morphology of the
664 articulating surfaces, mathematical description and mechanical functioning. Acta
665 Bioeng Biomech 2016;18:103-10.
- 666 19. Bettinger PC, Linscheid RL, Berger RA, Cooney WP 3rd, An KN. An anatomic study
667 of the stabilizing ligaments of the trapezium and trapeziometacarpal joint. J Hand
668 Surg Am 1999;24:786-98.
- 669 20. Bettinger PC, Berger RA. Functional ligamentous anatomy of the trapezium
670 and trapeziometacarpal joint (gross and arthroscopic). Hand Clin 2001;17:151-68, vii.
- 671 21. Chiavaras MM, Harish S, Oomen G, Popowich T, Wainman B, Bain JR. Sonography
672 of the anterior oblique ligament of the trapeziometacarpal joint: a study of cadavers
673 and asymptomatic volunteers. AJR Am J Roentgenol 2010;195:428-34.
- 674 22. Hirschmann A, Sutter R, Schweizer A, Pfirrmann CW. The carpometacarpal joint of
675 the thumb: MR appearance in asymptomatic volunteers. Skeletal Radiol
676 2013;42:1105-12.

- 677 23. Nanno M, Buford WL Jr, Patterson RM, Andersen CR, Viegas SF. Three-dimensional
678 analysis of the ligamentous attachments of the first carpometacarpal joint. *J Hand*
679 *Surg Am* 2006;31:1160-70.
- 680 24. Hallaj E, Moore DC, Patel TK, Laidlaw DH, Ladd AL, Weiss AP, Crisco JJ. Older
681 asymptomatic women exhibit patterns of thumb carpometacarpal joint space
682 narrowing that precede changes associated with early osteoarthritis. *J*
683 *Biomech* 2015;48:3634-40.
- 684 25. Kuhlmann JN, Guérin-Surville H. [Descriptive anatomy and biodynamic study of the
685 medial collateral ligament of the trapezio-metacarpal articulation of the thumb]. *Bull*
686 *Assoc Anat (Nancy)* 1985;69:315-30.
- 687 26. Bettinger PC, Smutz WP, Linscheid RL, Cooney WP 3rd, An KN. Material properties
688 of the trapezial and trapeziometacarpal ligaments. *J Hand Surg Am* 2000;25:1085-95.
- 689 27. Ladd AL, Lee J, Hagert E. Macroscopic and microscopic analysis of the thumb
690 carpometacarpal ligaments: a cadaveric study of ligament anatomy and histology. *J*
691 *Bone Joint Surg Am* 2012;94:1468-77.
- 692 28. Kuhlmann JN. [Importance of the posteromedial trapeziometacarpal ligamentous
693 complex]. *Chir Main* 2001;20:31-47.
- 694 29. Zhang AY, Van Nortwick S, Hagert E, Yao J, Ladd AL. Thumb carpometacarpal
695 ligaments inside and out: a comparative study of arthroscopic and
696 gross anatomy from the Robert A. Chase hand and upper limb center at Stanford
697 university. *J Wrist Surg* 2013;2:55-62.
- 698 30. Pellegrini VD Jr. Osteoarthritis of the trapeziometacarpal joint: the pathophysiology of
699 articular cartilage degeneration. II. Articular wear patterns in the osteoarthritic joint. *J*
700 *Hand Surg Am* 1991;16:975-82.
- 701 31. McCann MR, Rust PA, Wallace R. The stabilizing effect of the anterior oblique
702 ligament to prevent directional subluxation at the trapeziometacarpal joint of the
703 thumb: a biomechanical cadaveric study. *Arch Bone Joint Surg* 2018;6:105-11.

- 704 32. Imaeda T, An KN, Cooney WP 3rd, Linscheid R. Anatomy of trapeziometacarpal
705 ligaments. *J Hand Surg Am* 1993;18:226-31.
- 706 33. Comtet JJ, Rumelhart C, Chèze L, Fickry T. [The trapezio-metacarpal joint: the strain
707 of the ligaments as a function of the thumb position. Study on an enlarged model].
708 *Chir Main* 2006;25:185-92.
- 709 34. Najima H, Oberlin C, Alnot JY, Cadot B. Anatomical and biomechanical studies of the
710 pathogenesis of trapeziometacarpal degenerative arthritis. *J Hand Surg*
711 *Br* 1997;22:183-8.
- 712 35. Van Brenk B, Richards RR, Mackay MB, Boynton EL. A biomechanical assessment of
713 ligaments preventing dorsoradial subluxation of the trapeziometacarpal joint. *J Hand*
714 *Surg Am* 1998;23:607-11.
- 715 36. Colman M, Mass DP, Draganich LF. Effects of the deep anterior oblique and
716 dorsoradial ligaments on trapeziometacarpal joint stability. *J Hand Surg*
717 *Am* 2007;32:310-7.
- 718 37. Tan J, Xu J, Xie RG, Deng AD, Tang JB. In vivo length and changes of ligaments
719 stabilizing the thumb carpometacarpal joint. *J Hand Surg Am* 2011;36:420-7
- 720 38. Hagert E, Lee J, Ladd AL. Innervation patterns of thumb trapeziometacarpal joint
721 ligaments. *J Hand Surg Am* 2012;37:706-14.e1.
- 722 39. D'Agostino P, Kerkhof FD, Shahabpour M, Moermans JP, Stockmans F, Vereecke
723 EE. Comparison of the anatomical dimensions and mechanical properties of the
724 dorsoradial and anterior oblique ligaments of the trapeziometacarpal joint. *J Hand*
725 *Surg Am* 2014;39:1098-107.
- 726 40. Lin JD, Karl JW, Strauch RJ. Trapeziometacarpal joint stability: the evolving
727 importance of the dorsal ligaments. *Clin Orthop Relat Res* 2014;472:1138-45.
- 728 41. Halilaj E, Rainbow MJ, Moore DC, Laidlaw DH, Weiss AP, Ladd AL, Crisco JJ. In vivo
729 recruitment patterns in the anterior oblique and dorsoradial ligaments of the first
730 carpometacarpal joint. *J Biomech* 2015 Jul 16;48:1893-8.

- 731 42. Esplugas M, Lluch-Bergada A, Mobargha N, Llusa-Perez M, Hagert E, Garcia-Elias
732 M2. Trapeziometacarpal ligaments biomechanical study: implications in arthroscopy.
733 J Wrist Surg 2016;5:277-83.
- 734 43. Mobargha N, Ludwig C, Ladd AL, Hagert E. Ultrastructure and innervation of
735 thumb carpometacarpal ligaments in surgical patients with osteoarthritis. Clin Orthop
736 Relat Res 2014;472:1146-54.
- 737 44. D'Agostino P, Dourthe B, Kerkhof F, Stockmans F, Vereecke EE. In vivo kinematics
738 of the thumb during flexion and adduction motion: Evidence for a screw-home
739 mechanism. J Orthop Res 2017;35:1556-64.
- 740 45. Kerkhof F, Brugman E, D'Agostino P, Dourthe B, van Lenthe G, Stockmans F,
741 Jonkers I, Vereecke E.E. Quantifying thumb opposition kinematics using dynamic CT.
742 J Biomech 2016; 49:1994-9.
- 743 46. Hume MC, Gellman H, McKellop H, Brumfield RH. Functional range of motion of the
744 joints of the hand. J Hand Surg 1990;15:240-3.
- 745 47. Yoshida R, House HO, Patterson RM, Shah MA, Viegas SF. Motion and morphology
746 of the thumb metacarpophalangeal joint. J Hand Surg 2003;28:753-7.
- 747 48. Murai T, Uchiyama S, Nakamura K, Ido Y, Hata Y, Kato H. Functional range of motion
748 in the metacarpophalangeal joints of the hand measured by single axis electric
749 goniometers. J Orthop Sci 2018;23:504-10.
- 750 49. Lin HT, Kuo LC, Liu HY, Wu WL, Su FC. The three-dimensional analysis of three
751 thumb joints coordination in activities of daily living. Clin Biomech (Bristol,
752 Avon) 2011;26:371-6.
- 753 50. van Oudenaarde E, Oostendorp R. Significance of the innervation pattern of the
754 human abductor pollicis longus muscle. J Anat 1992;181:155-9.
- 755 51. Bouchlis G, Bhatia A, Asfazadourian H, Touam C, Vacher C, Oberlin C. Distal
756 insertions of abductor pollicis longus muscle and arthritis of the first carpometacarpal
757 joint in 104 dissections. Ann Chir Main Memb Super 1997;16:326-38.

- 758 52. El-Beshbishy RA, Abdel-Hamid GA. Variations of the abductor pollicis longus tendon:
759 an anatomic study. *Folia Morphol (Warsz)* 2013;72:161-6.
- 760 53. Kauer JM. Functional anatomy of the carpometacarpal joint of the thumb. *Clin Orthop*
761 *Relat Res* 1987;220:7-13.
- 762 54. Smutz WP, Kongsayreepong A, Hughes RE, Niebur G, Cooney WP, An KN.
763 Mechanical advantage of the thumb muscles. *J Biomech* 1998;31:565-70.
- 764 55. Roh MS, Strauch RJ, Xu L, Rosenwasser MP, Pawluk RJ, Mow VC. Thenar insertion
765 of abductor pollicis longus accessory tendons and thumb carpometacarpal
766 osteoarthritis. *J Hand Surg Am* 2000;25:458-63.
- 767 56. Schulz CU, Anetzberger H, Pfahler M, Maier M, Refior HJ. The relation between
768 primary osteoarthritis of the trapeziometacarpal joint and supernumerary slips of the
769 abductor pollicis longus tendon. *J Hand Surg Br* 2002;27:238-41.
- 770 57. Roush TF, Aldridge JM, Berger RA, Rizzo M. No correlation between
771 trapeziometacarpal arthritis and abductor pollicis longus insertion. *Clin Orthop Relat*
772 *Res* 2005;434:138-42.
- 773 58. Jabir S, Lyall H, Iwuagwu FC. The extensor pollicis brevis: a review of its anatomy
774 and variations. *Eplasty* 2013;13:e35.
- 775 59. Brunelli GA, Brunelli GR. Anatomy of the extensor pollicis brevis muscle. *J Hand Surg*
776 *Br* 1992;17:267-9.
- 777 60. Kulshreshtha R, Patel S, Arya AP, Hall S, Compson JP. Variations of the extensor
778 pollicis brevis tendon and its insertion: a study of 44 cadaveric hands. *J Hand Surg*
779 *Eur* 2007; 32:550-3.
- 780 61. Li ZM, Tang J, Chakan M, Kaz R. Complex, multidimensional thumb movements
781 generated by individual extrinsic muscles. *J Orthop Res* 2008;26:1289-95.
- 782 62. McGee C, O'Brien V, Van Nortwick S, Adams J, Van Heest A. First dorsal
783 interosseous muscle contraction results in radiographic reduction of healthy thumb
784 carpometacarpal joint. *J Hand Ther* 2015;28:375-80; quiz 381.

- 785 63. Mobargha N, Esplugas M, Garcia-Elias M, Lluch A, Megerle K, Hagert E. The effect
786 of individual isometric muscle loading on the alignment of the base of the thumb
787 metacarpal: a cadaveric study. *J Hand Surg Eur* 2016;41:374-9.
- 788 64. Cooney WP, An KN, Daube JR, Askew LJ. Electromyographic analysis of the thumb:
789 a study of isometric forces in pinch and grasp. *J Hand Surg* 1985;10:202-10
- 790 65. Kerkhof FD, Deleu G, D'Agostino P, Vereecke EE. Subject-specific thumb muscle
791 activity during functional tasks of daily life. *J Electromyogr Kinesiol* 2016;30:131-6.
- 792 66. Srinivasan H, Landsmeer JM. Internal stabilization in the thumb. *J Hand Surg*
793 *Am* 1982;7:371-5.
- 794 67. Goubau JF, Benis S, Van Hoonacker P, Berghs B, Kerckhove D, Patonay L.
795 Vascularization of the trapeziometacarpal joint and its clinical importance: anatomical
796 study. *Chir Main* 2012;31:57-61.
- 797 68. Messina A. [Vascularized surgical rotation of a bi-articular trapezoid-
798 trapeziometacarpal complex for the treatment of severe rhizarthrosis of the thumb].
799 *Chir Main* 2000;19:134-40.
- 800 69. Loréa P, Dury M, Marin Braun F, Dekkaï T, De Mey A, Foucher G.
801 [Trapeziometacarpal denervation. Description of surgical technique and preliminary
802 results from a prospective series of 14 cases]. *Chir Main* 2002;21:209-17.
- 803 70. Loréa P, Berthe JV, De Mey A, Coessens BC, Rooze M, Foucher G. [Thenar branch
804 of the median nerve and innervation of the trapeziometacarpal joint]. *Chir*
805 *Main* 2001;20:257-62.
- 806 71. Loréa DP, Berthe JV, De Mey A, Coessens BC, Rooze M, Foucher G. The nerve
807 supply of the trapeziometacarpal joint. *J Hand Surg Br* 2002;27:232-7.
- 808 72. Poupon M, Duteille F, Cassagnau E, Leborgne J, Pannier M. [Anatomical study of the
809 nerve supply of the trapeziometacarpal joint. Fifteen dissections]. *Rev Chir Orthop*
810 *Reparatrice Appar Mot* 2004;90:346-52.

- 811 73. Miki RA, Kam CC, Gennis ER, Barkin JA, Riel RU, Robinson PG, Owens PW. Ulnar
812 nerve component to innervation of thumb carpometacarpal joint. *Iowa Orthop J*
813 2011;31:225-30.
- 814 74. Loréa PD. First carpometacarpal joint denervation: anatomy and surgical technique.
815 *Tech Hand Up Extrem Surg* 2003;7:26-31.
- 816 75. Espinosa Gutiérrez A, Trujillo Millán A, Ramírez Lozano G, Romo Rodríguez
817 R, Zárate Ramírez G. [Arthroscopy of the trapeziometacarpal joint: anatomical study
818 on cadavers]. *Acta Ortop Mex* 2008;22:402-4.
- 819 76. Napier JR. The form and function of the carpo-metacarpal joint of the thumb. *J*
820 *Anat* 1955;89:362-9.
- 821 77. Dourthe B, D'Agostino P, Stockmans F, Kerkhof F, Vereecke E. In vivo
822 contact biomechanics in the trapeziometacarpal joint using finite deformation biphasic
823 theory and mathematical modeling. *Med Eng Phys*. 2016;38:108-14.
- 824 78. Momose T, Nakatsuchi Y, Saitoh S. Contact area of the trapeziometacarpal joint. *J*
825 *Hand Surg Am* 1999;24:491-5.
- 826 79. Ateshian GA, Ark JW, Rosenwasser MP, Pawluk RJ, Soslowsky LJ, Mow VC.
827 Contact areas in the thumb carpometacarpal joint. *J Orthop Res* 1995;13:450-8.
- 828 80. Halilaj E, Rainbow MJ, Got C, Schwartz JB, Moore DC, Weiss AP, Ladd AL, Crisco
829 JJ. In vivo kinematics of the thumb carpometacarpal joint during three isometric
830 functional tasks. *Clin Orthop Relat Res* 2014;472:1114-22.
- 831 81. Cooney WP 3rd, Chao EYS. Biomechanical analysis of static forces in the thumb
832 during hand function. *J Bone Joint Surg Am* 1977;59:27-36.
- 833 82. Zancolli EA, Zaidenberg C, Zancolli E Jr. Biomechanics of
834 the trapeziometacarpal joint. *Clin Orthop Relat Res* 1987;220:14-26.
- 835 83. Chèze L, Doriot N, Eckert M, Rumelhart C, Comtet JJ. [In vivo cinematic study of the
836 trapeziometacarpal joint]. *Chir Main* 2001;20:23-30.

- 837 84. Crisco JJ, Halilaj E, Moore DC, Patel T, Weiss AP, Ladd AL. In vivo kinematics of
838 the trapeziometacarpal joint during thumb extension-flexion and abduction-adduction.
839 J Hand Surg Am 2015;40:289-96.
- 840 85. Halilaj E, Moore DC, Patel TK, Laidlaw DH, Ladd AL, Weiss AP, Crisco JJ.
841 Thumb carpometacarpal joint congruence during functional tasks and thumb range-
842 of-motion activities. Conf Proc IEEE Eng Med Biol Soc 2014;2014:4354-7.
- 843 86. Schneider MT, Zhang J, Crisco JJ, Weiss AP, Ladd AL, Nielsen P, Besier T. Men and
844 women have similarly shaped carpometacarpal joint bones. J Biomech 2015
845 18;48:3420-6.
- 846 87. Ateshian GA, Rosenwasser MP, Mow VC. Curvature characteristics and congruence
847 of the thumb carpometacarpal joint: differences between female and male joints. J
848 Biomech 1992;25:591-607.
- 849 88. Halilaj E, Moore DC, Laidlaw DH, Got CJ, Weiss AP, Ladd AL, Crisco JJ. The
850 morphology of the thumb carpometacarpal joint does not differ between men and
851 women, but changes with aging and early osteoarthritis. J Biomech 2014 22;47:2709-
852 14.
- 853 89. Kihara H. [Anatomical study of the normal and degenerative articular surfaces on the
854 first carpometacarpal joint]. Nihon Seikeigeka Gakkai Zasshi 1992;66:228-39.
- 855 90. Wolf JM, Oren TW, Ferguson B, Williams A, Petersen B. The carpometacarpal stress
856 view radiograph in the evaluation of trapeziometacarpal joint laxity. J Hand Surg Am.
857 2009;34:1402-6.
- 858 91. Jónsson H, Elíasson GJ, Jónsson A, Eiríksdóttir G, Sigurdsson S, Aspelund T, Harris
859 TB, Gudnason V. High hand joint mobility is associated with radiological CMC1
860 osteoarthritis: the AGES-Reykjavik study. Osteoarthritis Cartilage 2009;17:592-5.
- 861 92. Wolf JM, Schreier S, Tomsick S, Williams A, Petersen B. Radiographic laxity of
862 the trapeziometacarpal joint is correlated with generalized joint hypermobility. J Hand
863 Surg Am 2011;36:1165-9.

- 864 93. Kraus VB, Li YJ, Martin ER, Jordan JM, Renner JB, Doherty M, Wilson
865 AG, Moskowitz R, Hochberg M, Loeser R, Hooper M, Sundseth S. Articular
866 hypermobility is a protective factor for hand osteoarthritis. *Arthritis*
867 *Rheum* 2004;50:2178-83.
- 868 94. Pellegrini VD Jr, Olcott CW, Hollenberg G. Contact patterns in
869 the trapeziometacarpal joint: the role of the palmar beak ligament. *J Hand Surg*
870 *Am* 1993;18:238-44.
- 871 95. Kwok WY, Kloppenburg M, Marshall M, Nicholls E, Rosendaal FR, Peat G. The
872 prevalence of erosive osteoarthritis in carpometacarpal joints and its clinical burden in
873 symptomatic community-dwelling adults. *Osteoarthritis Cartilage* 2014;22:756-63.
- 874 96. Moriatis Wolf J, Turkiewicz A, Atroshi I, Englund M. Prevalence of doctor-diagnosed
875 thumb carpometacarpal joint osteoarthritis: an analysis of Swedish health care.
876 *Arthritis Care Res (Hoboken)* 2014;66:961-5.
- 877 97. Armstrong AL, Hunter JB, Davis TR. The prevalence of degenerative arthritis of the
878 base of the thumb in post-menopausal women. *J Hand Surg Br* 1994;19:340-1.
- 879 98. Brown GD 3rd, Roh MS, Strauch RJ, Rosenwasser MP, Ateshian GA, Mow VC.
880 Radiography and visual pathology of the osteoarthritic scaphotrapeziotrapezoid joint,
881 and its relationship to trapeziometacarpal osteoarthritis. *J Hand Surg*
882 *Am* 2003;28:739-43.
- 883 99. Scordino LE, Bernstein J, Nakashian M, McIntosh M, Cote MP, Rodner CM, Wolf JM.
884 Radiographic prevalence of scaphotrapeziotrapezoid osteoarthrosis. *J Hand Surg*
885 *Am* 2014;39:1677-82.
- 886 100. Maes-Clavier C, Bellemère P, Gabrion A, David E, Rotari V, Havet E.
887 Anatomical study of the ligamentous attachments and articular surfaces of the
888 trapeziometacarpal joint. Consequences on surgical management of its
889 osteoarthrosis. *Chir Main* 2014;33:118-23.

- 890 101. Koff MF, Ugwonalu OF, Strauch RJ, Rosenwasser MP, Ateshian GA, Mow VC.
891 Sequential wear patterns of the articular cartilage of the thumb carpometacarpal joint
892 in osteoarthritis. *J Hand Surg Am* 2003;28:597-604.
- 893 102. Shi Q, Hashizume H, Inoue H, Miyake T, Nagayama N. Finite element
894 analysis of pathogenesis of osteoarthritis in the first carpometacarpal joint. *Acta Med*
895 *Okayama* 1995;49:43-51.
- 896 103. Momose T. [Cartilage degeneration and measurement of the contact area of
897 the trapeziometacarpal joint: morphological observation]. *Nihon Seikeigeka Gakkai*
898 *Zasshi* 1994;68:426-34.
- 899 104. D'Agostino P, Dourthe B, Kerkhof F, van Lenthe GH, Stockmans F, Vereecke
900 EE. In vivo biomechanical behavior of the trapeziometacarpal joint in healthy and
901 osteoarthritic subjects. *Clin Biomech (Bristol, Avon)* 2017;49:119-27.
- 902 105. Xu L, Strauch RJ, Ateshian GA, Pawluk RJ, Mow VC, Rosenwasser MP.
903 Topography of the osteoarthritic thumb carpometacarpal joint and its variations with
904 regard to gender, age, site, and osteoarthritic stage. *J Hand Surg Am* 1998;23:454-
905 64.
- 906 106. Nufer P, Goldhahn J, Kohler T, Kuhn V, Müller R, Herren DB. Microstructural
907 adaptation in trapezial bone due to subluxation of the thumb. *J Orthop*
908 *Res* 2008;26:208-16.
- 909 107. Lee AT, Williams AA, Lee J, Cheng R, Lindsey DP, Ladd AL. Trapezium
910 trabecular morphology in carpometacarpal arthritis. *J Hand Surg Am* 2013;38:309-15.
- 911 108. Kovler M, Landon K, McKee N, Agur A. The human first carpometacarpal joint:
912 osteoarthritic degeneration and 3-dimensional modeling. *J Hand Ther* 2004;17:393-
913 400.
- 914 109. Doerschuk SH, Hicks DG, Chinchilli VM, Pellegrini VD Jr. Histopathology of
915 the palmar beak ligament in trapeziometacarpal osteoarthritis. *J Hand Surg Am*
916 1999;24:496-504.

- 917 110. Pellegrini VD Jr. Comparative pathoanatomy of the Asian and
918 Caucasian trapeziometacarpal joint. *Ann Acad Med Singapore* 1995;24(4 Suppl):21-
919 5.
- 920 111. Omokawa S, Ryu J, Tang JB, Han J, Kish VL. Trapeziometacarpal joint
921 instability affects the moment arms of thumb motor tendons. *Clin Orthop Relat*
922 *Res* 2000;372:262-71.
- 923 112. Miura T, Ohe T, Masuko T. Comparative in vivo kinematic analysis of normal
924 and osteoarthritic trapeziometacarpal joints. *J Hand Surg Am* 2004;29:252-7.
- 925 113. D'Agostino P, Dourthe B, Kerkhof F, Vereecke EE, Stockmans F. Impact of
926 osteoarthritis and total joint arthroplasty on the kinematics of the trapeziometacarpal
927 joint. *J Hand Surg Am* 201843:382.e1-382.e10.
- 928 114. Schöneberger M, Koebke J. [Rhizarthrosis and thenar muscles. A clinico-
929 anatomic study]. *Handchir Mikrochir Plast Chir* 1989;21:182-8.
- 930 115. Pellegrini VD Jr, Smith RL, Ku CW. Pathobiology of articular cartilage
931 in trapeziometacarpal osteoarthritis. II. Surface ultrastructure by scanning electron
932 microscopy. *J Hand Surg Am* 1994;19:79-85.
- 933 116. Rivers PA, Rosenwasser MP, Mow VC, Pawluk RJ, Strauch RJ, Sugalski
934 MT, Ateshian GA. Osteoarthritic changes in the biochemical composition of
935 thumb carpometacarpal joint cartilage and correlation with biomechanical properties.
936 *J Hand Surg Am* 2000;25:889-98.
- 937 117. Clifton KB, Rodner C, Wolf JM. Detection of relaxin receptor in the dorsoradial
938 ligament, synovium, and articular cartilage of the trapeziometacarpal joint. *J Orthop*
939 *Res* 2014;32:1061-7.
- 940 118. Gehrman SV, Tang J, Li ZM, Goitz RJ, Windolf J, Kaufmann RA. Motion
941 deficit of the thumb in CMC joint arthritis. *J Hand Surg Am* 2010;35:1449-53.
- 942 119. Wu JZ, Li ZM, Cutlip RG, An KN. A simulating analysis of the effects of
943 increased joint stiffness on muscle loading in a thumb. *Biomed Eng Online* 2009;8:41.

- 944 120. McQuillan TJ, Kenney D, Crisco JJ, Weiss AP, Ladd AL. Weaker functional
945 pinch strength is associated with early thumb carpometacarpal osteoarthritis. Clin
946 Orthop Relat Res 2016;474:557-61.
- 947 121. Coughlan MJ, Bourdillon A, Crisco JJ, Kenney D, Weiss AP, Ladd AL.
948 Reduction in cylindrical grasp strength is associated with early
949 thumb carpometacarpal osteoarthritis. Clin Orthop Relat Res 2017;475:522-8.
- 950 122. Villafañe JH, Valdes K. Combined thumb abduction and index finger extension
951 strength: a comparison of older adults with and without thumb carpometacarpal
952 osteoarthritis. J Manipulative Physiol Ther 2013;36:238-44.
- 953 123. Cantero-Télez R, Martín-Valero R, Cuesta-Vargas A. Effect of muscle
954 strength and pain on hand function in patients with trapeziometacarpal osteoarthritis.
955 A cross-sectional study. Reumatol Clin 2015;11:340-4.
- 956 124. Dominick KL, Jordan JM, Renner JB, Kraus VB. Relationship of radiographic
957 and clinical variables to pinch and grip strength among individuals with osteoarthritis.
958 Arthritis Rheum 2005;52:1424-30.
- 959 125. Halilaj E, Moore DC, Patel TK, Ladd AL, Weiss AP, Crisco JJ. Early
960 osteoarthritis of the trapeziometacarpal joint is not associated with joint instability
961 during typical isometric loading. J Orthop Res 2015;33:1639-45.
- 962 126. Lovati AB, Colombini A, Recordati C, Ceriani C, Zagra L, Berzero G, Moretti
963 M. Chondrogenic capability of osteoarthritic chondrocytes from
964 the trapeziometacarpal and hip joints. Cell Tissue Bank 2016;17:171-7.
- 965 127. Ledoux P. M1/M2 Ratio for radiological follow-up of trapeziometacarpal
966 surgery. Hand Surg Rehabil 2017 ;36:146-7.
- 967 128. Moulton MJ, Parentis MA, Kelly MJ, Jacobs C, Naidu SH, Pellegrini VD Jr.
968 Influence of metacarpophalangeal joint position on basal joint-loading in the thumb. J
969 Bone Joint Surg Am 2001;83:709-16.

- 970 129. Koff MF, Zhao KD, Mierisch CM, Chen MY, An KN, Cooney WP 3rd. Joint
971 kinematics after thumb carpometacarpal joint reconstruction: an in vitro comparison of
972 various constructs. *J Hand Surg Am* 2007;32:688-96.
- 973 130. Domalain MF, Seitz WH, Evans PJ, Li ZM. Biomechanical effect of increasing
974 or decreasing degrees of freedom for surgery of trapeziometacarpal joint arthritis: a
975 simulation study. *J Orthop Res* 2011;29:1675-81.
- 976 131. Duerinckx J, Caekebeke P. Trapezium anatomy as a radiographic reference
977 for optimal cup orientation in total trapeziometacarpal joint arthroplasty. *J Hand Surg*
978 *Eur* 2016;41:939-43.
- 979 132. Oberlin C. [Comparative anatomy of the hand]. *Chir Main* 2006;25:111-8.
- 980 133. Marzke MW, Tocheri MW, Steinberg B, Femiani JD, Reece SP, Linscheid
981 RL, Orr CM, Marzke RF. Comparative 3D quantitative analyses
982 of trapeziometacarpal joint surface curvatures among living catarrhines and fossil
983 hominins. *Am J Phys Anthropol* 2010;141:38-51.
- 984 134. van Leeuwen T, Vanneste M, Kerkhof F, D'Agostino P, Vanhoof M, Stevens J,
985 van Lenthe GH, Vereeck EE. Mobility and structural constraints of the bonobo
986 trapeziometacarpal joint. *Biol J Linn Soc Lond* 2019;127:681-93.
- 987 135. Marzke MW, Marzke RF, Linscheid RL, Smutz P, Steinberg B, Reece S, An
988 KN. Chimpanzee thumb muscle cross sections, moment arms and potential torques,
989 and comparisons with humans. *Am J Phys Anthropol* 1999;110:163-78.
- 990 136. Marzke MW. Evolutionary development of the human thumb. *Hand*
991 *Clin* 1992;8:1-8.

992

993

994 **Figure legends**

995 Fig. 1. Distal (A) and palmar (B) view of the trapeziometacarpal after the first metacarpal has
996 been removed. The axes around which abduction-adduction (K-wire A) and antepulsion-
997 retropulsion (K-wire B, entering the palmar beak of trapezium) occur are not completely
998 orthogonal, are not secant and are not located in the reference planes (from Zancolli and
999 Cozzi, Atlas of surgical anatomy of the hand. Churchill Livingstone 1992). *H*: hook of hamate;
1000 *L*: anterior horn of lunate; *P*: pisiform; *S*: scaphoid; *T*: trapezium.

1001 Fig. 2. Anatomy of trapezium. Palmar (A), dorsal (B), medial (C) and distal (D) views. *FCR*:
1002 flexor carpi radialis; *M*: articular surface for 1st metacarpal; *S*: articular surface for scaphoid;
1003 *T*: articular surface for trapezoid

1004 Fig. 3. Anterior (A) and lateral (B) views of the trapeziometacarpal joint. *APL*: abductor
1005 pollicis longus ; *dAOL*: deep anterior oblique ligament (visible through a window in the
1006 *sAOL*); *DIML*: dorsal intermetacarpal ligament ; *DRL*: dorsoradial ligament ; *FCR*: flexor carpi
1007 radialis ; *IML*: intermetacarpal ligament ; *POL*: posterior oblique ligament ; *sAOL*: superficial
1008 anterior oblique ligament ; *UCL*: ulnar collateral ligament.

1009 Fig. 4. The distally inserting tendons of the abductor pollicis longus (lateral view, left hand).
1010 This dissection shows three tendons ending on the 1) muscle body of the abductor pollicis
1011 brevis, 2) the trapeziometacarpal capsule, 3) the first metacarpal base.

1012 Fig. 5. To generate a 1 kg pinch grip, the trapeziometacarpal joint supports 10 kg of load
1013 (from Cooney & Chao [76]).

1014

Figure 1A

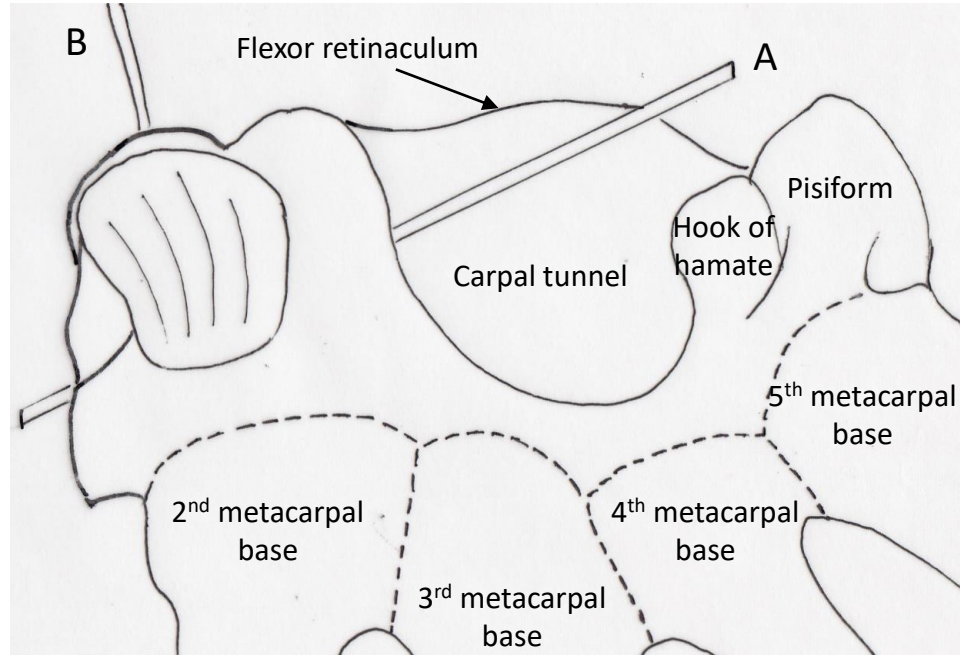


Figure 1B

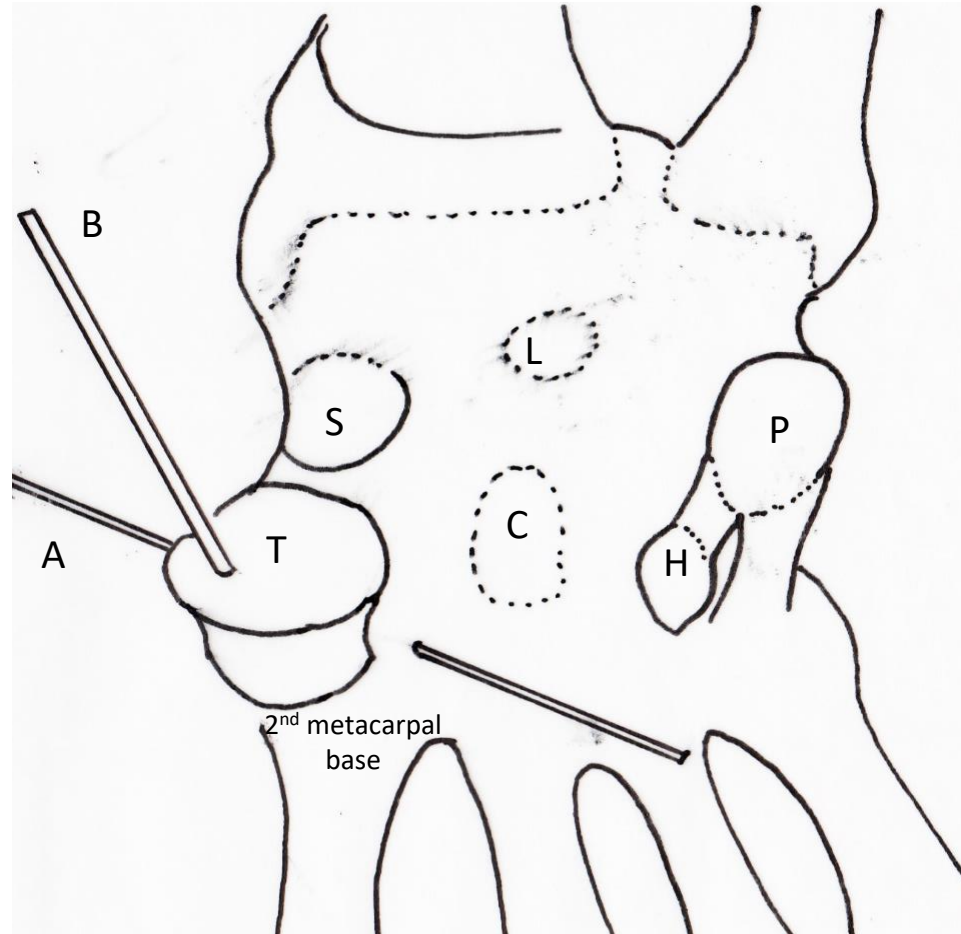


Figure 2A

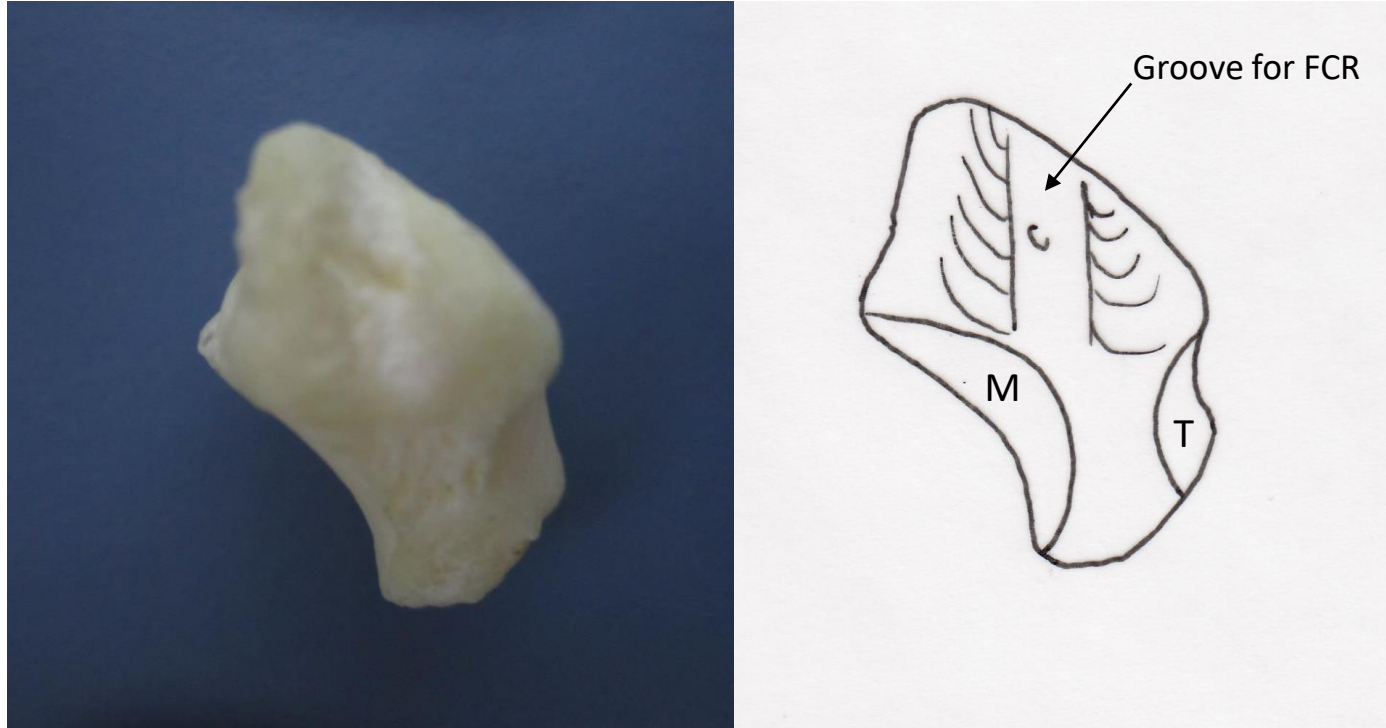


Figure 2B

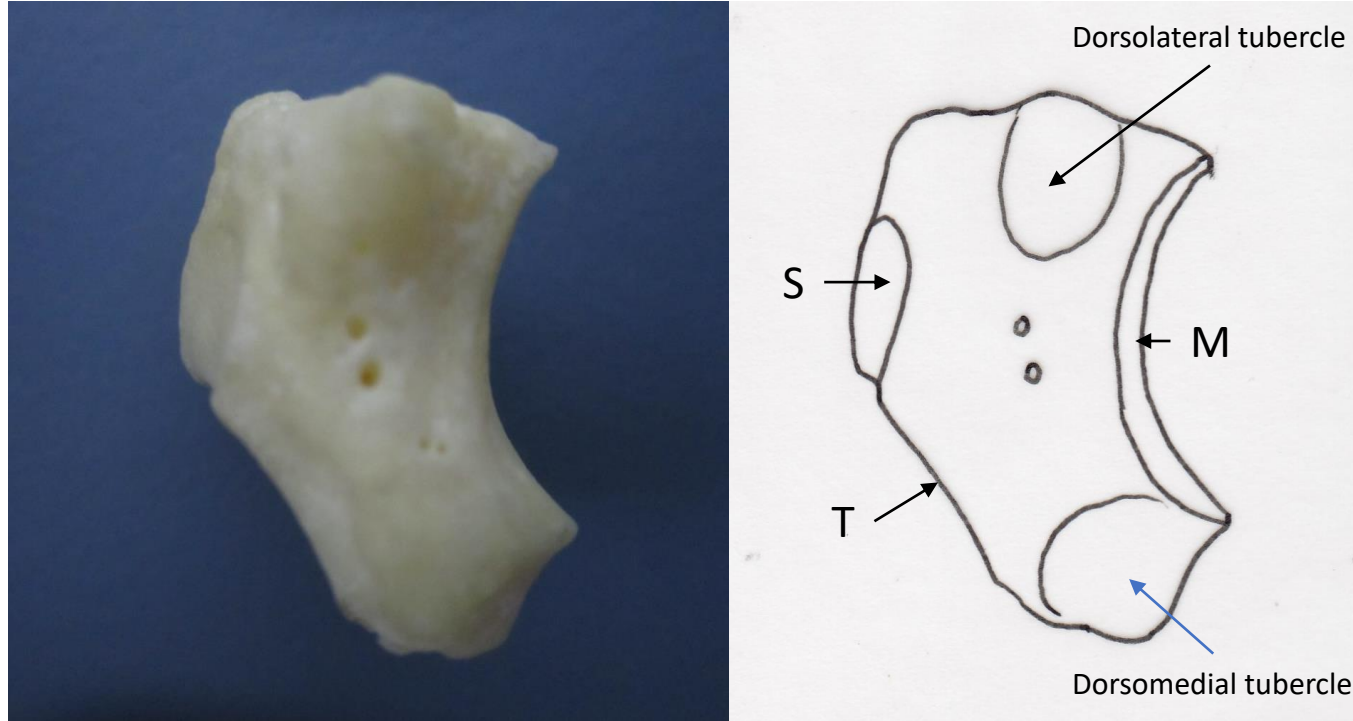


Figure 2C

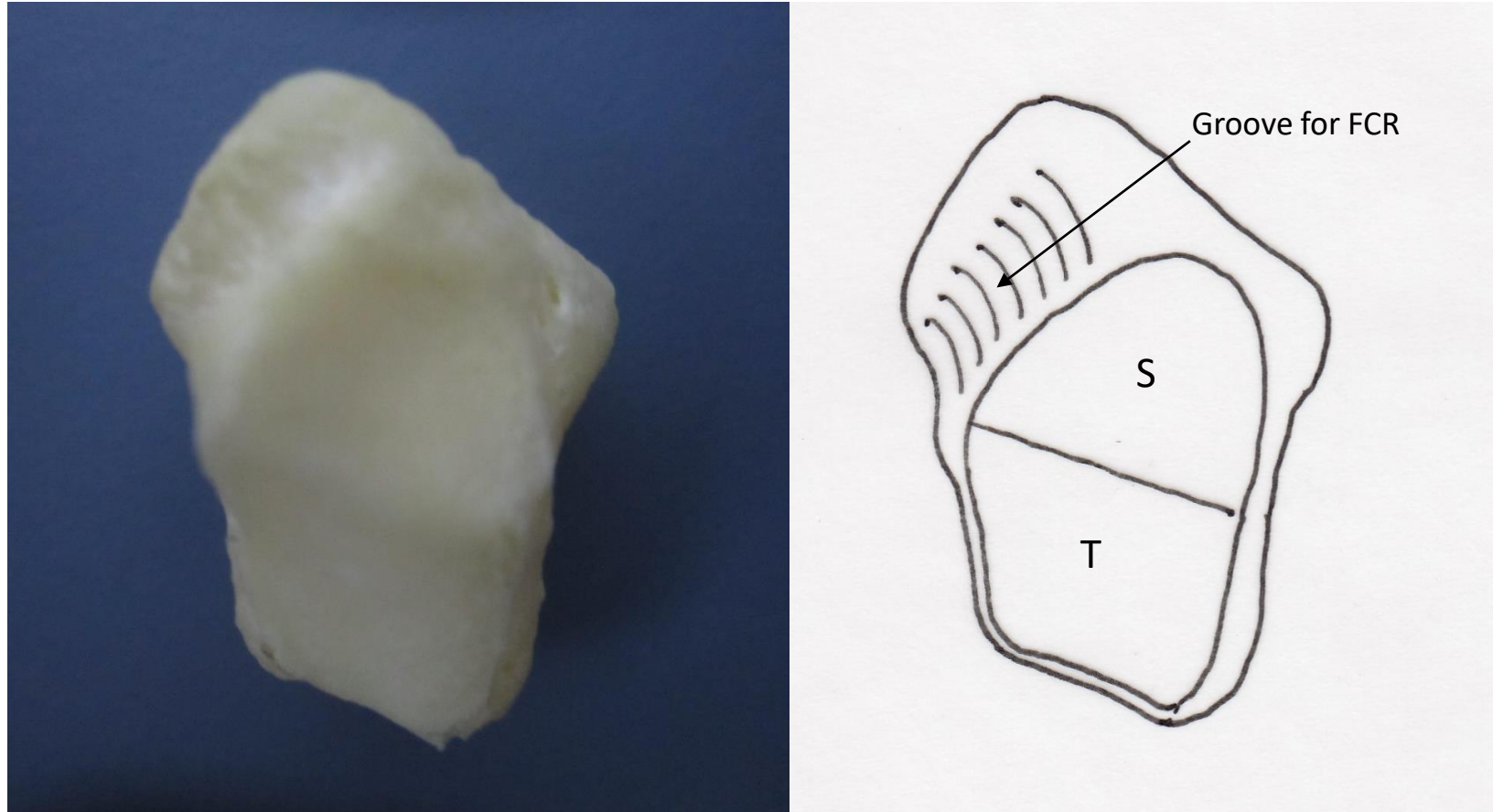


Figure 2D

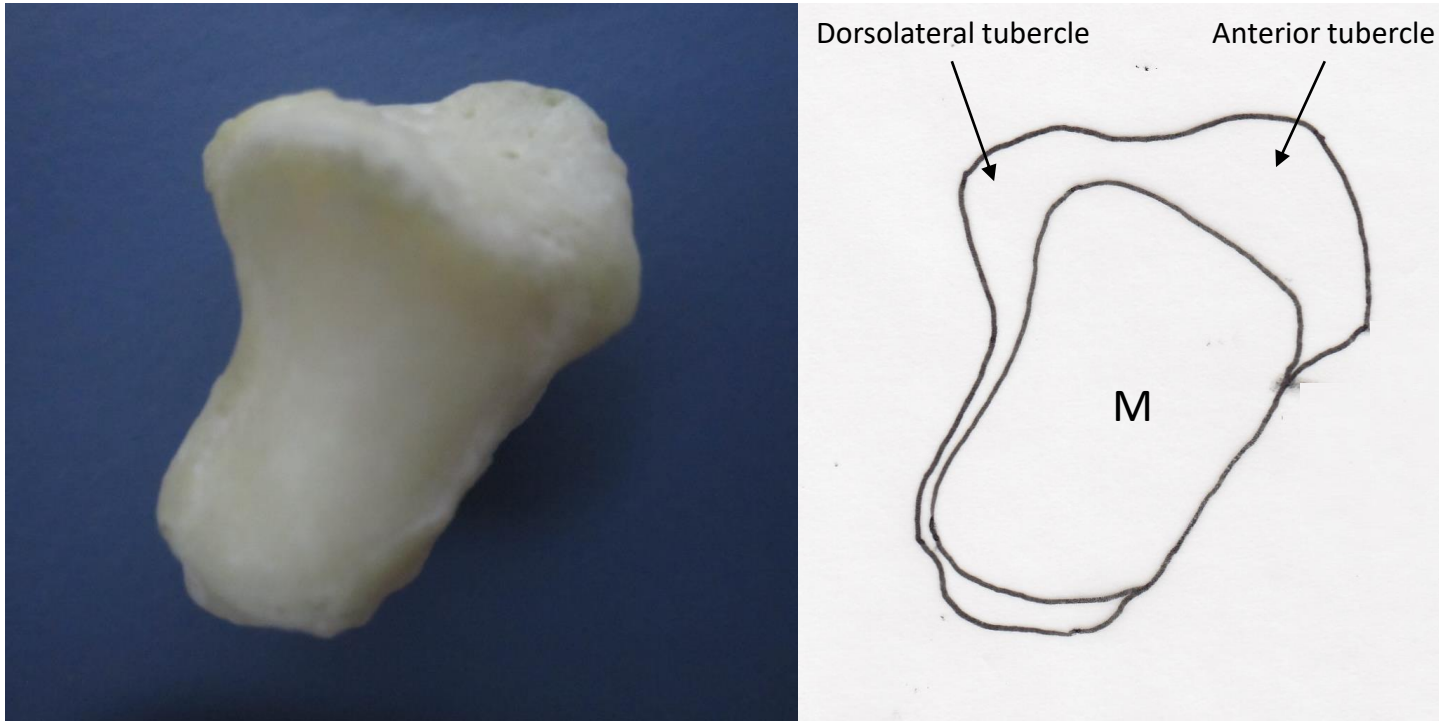


Figure 3A

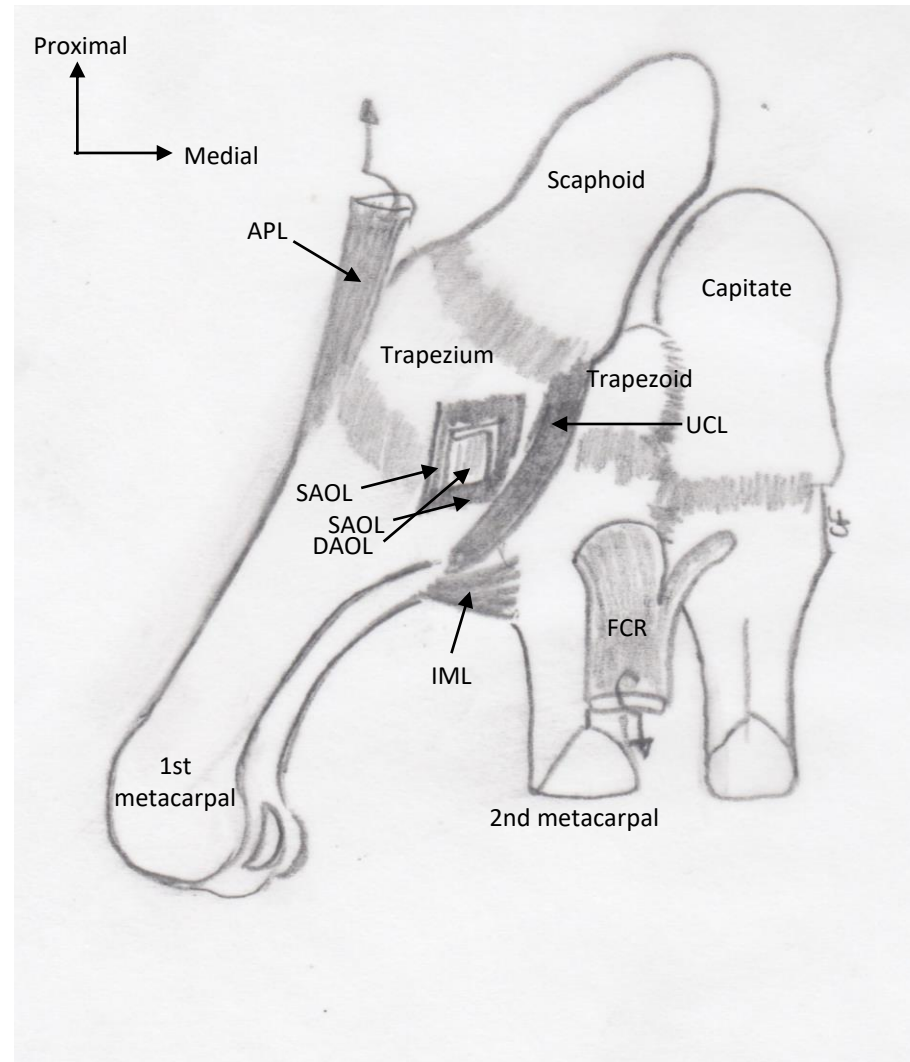


Figure 3B

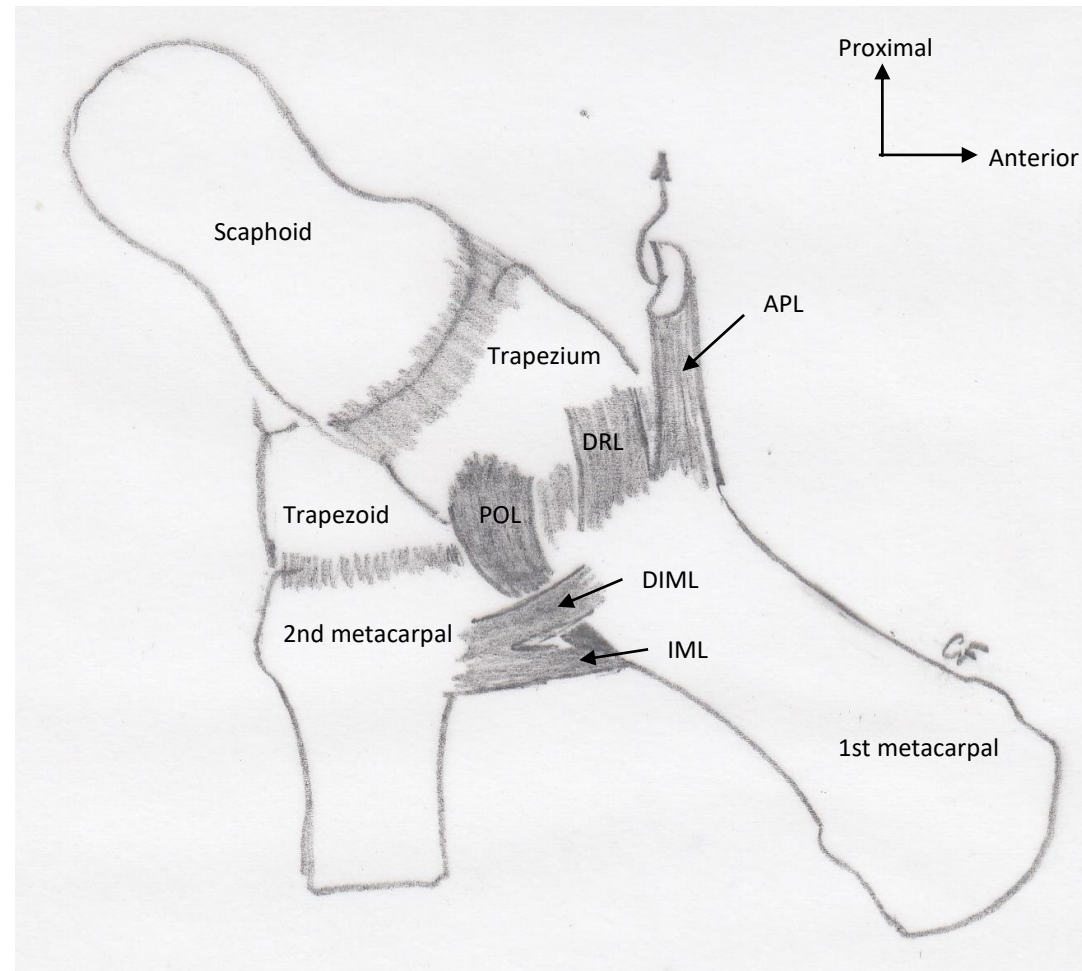


Figure 4

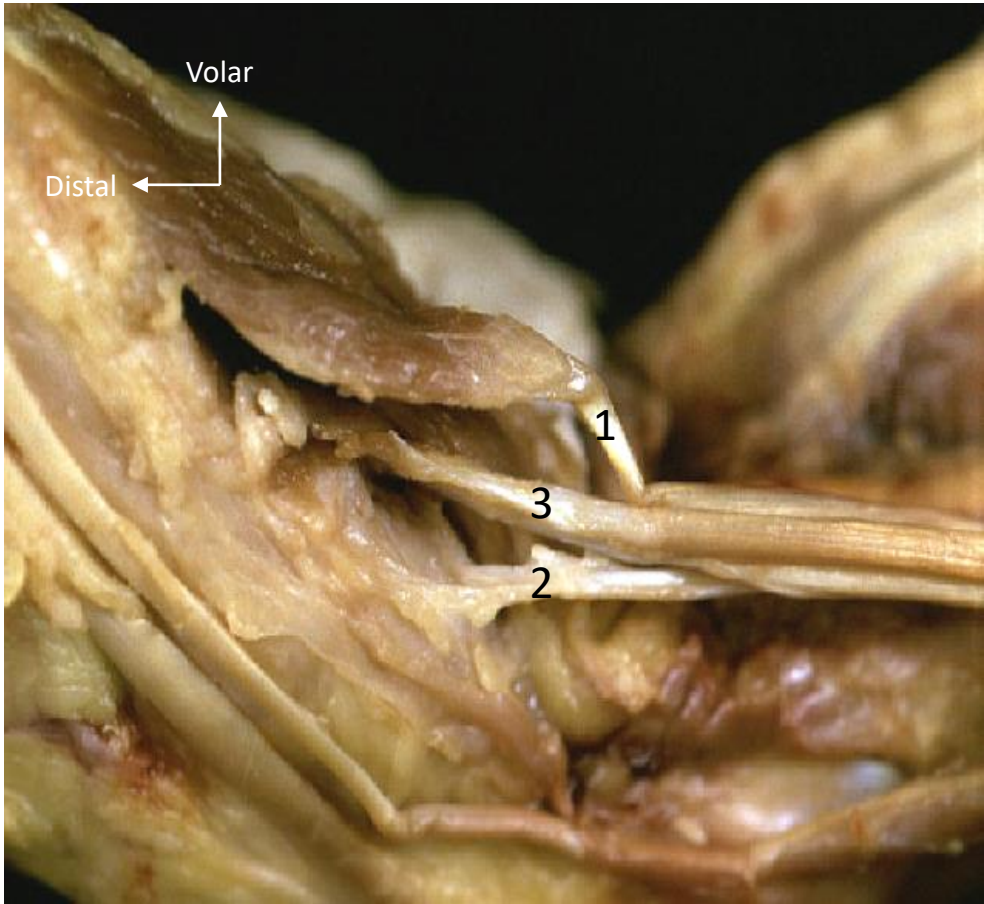



Figure 5

