



Anatomy and biomechanics of healthy and arthritic trapeziometacarpal joints

Christian Fontaine, P. D'agostino, Catherine Maes-Clavier, M. Boutan,
Nadine Sturbois-Nachef

► To cite this version:

Christian Fontaine, P. D'agostino, Catherine Maes-Clavier, M. Boutan, Nadine Sturbois-Nachef. Anatomy and biomechanics of healthy and arthritic trapeziometacarpal joints. *Hand Surgery and Rehabilitation*, 2021, 40, pp.3-14. 10.1016/j.hansur.2020.09.014 . hal-03710392

HAL Id: hal-03710392

<https://uphf.hal.science/hal-03710392>

Submitted on 22 Aug 2023

HAL is a multi-disciplinary open access archive for the deposit and dissemination of scientific research documents, whether they are published or not. The documents may come from teaching and research institutions in France or abroad, or from public or private research centers.

L'archive ouverte pluridisciplinaire **HAL**, est destinée au dépôt et à la diffusion de documents scientifiques de niveau recherche, publiés ou non, émanant des établissements d'enseignement et de recherche français ou étrangers, des laboratoires publics ou privés.



Distributed under a Creative Commons Attribution - NonCommercial 4.0 International License

Anatomy and biomechanics of healthy and arthritic CMC1 joint

Anatomie et biomécanique de l'articulation trapézo-métacarpienne saine et arthrosique

C. Fontaine^{1,2,3}, P. D'Agostino⁴, C. Maes-Clavier⁵, M. Boutan⁶, N. Sturbois-Nachef³

1 : Laboratoire d'anatomie et organogenèse, Faculté de Médecine Henri Warembourg, Université de Lille, Rue Michel Polonovski, 59045 Lille cedex, France

2 : Laboratoire d'Automatique, de Mécanique et d'informatique industrielle et Humaine LAMIH, Université de Valenciennes et du Hainaut-Cambrésis, Le Mont Houy, 59313 Valenciennes cedex, France

3 : Clinique de Traumatologie-Orthopédie, Hôpital Roger Salengro, Rue du Professeur Emile Laine, CHRU de Lille, 59037 Lille cedex, France

4 : Clinique de la Main, Bruxelles et Brabant-Wallon, Avenue Louise 284, 1050 Bruxelles, Belgique

5 : Service de chirurgie orthopédique et traumatologique, CHU Amiens-Picardie, Site sud Route départementale 408, 80054 Amiens cedex 1, France

6 : Résidence Dryades, Bâtiment A1, 1, rue du 11 novembre, 40990 Saint-Paul-les-Dax, France

Auteur correspondant :

Pr Christian Fontaine

Laboratoire d'anatomie et organogenèse – Faculté de Médecine Henri Warembourg – Université de Lille – Place de Verdun – 59045 Lille cedex – France

Tel : 06 62 26 33 83

Fax : 03 20 44 67 71

christian.fontaine@chru-lille.fr

Conflits d'intérêts :

C. Fontaine : Essais cliniques : en qualité de co-investigateur, expérimentateur non principal, collaborateur à l'étude pour Hospital & Healthcare Consulting. Conférences : invitations en qualité d'intervenant pour Allergan, IPSEN et MERZ. Il n'a pas d'autres liens d'intérêt.

Les autres auteurs n'ont pas de conflit d'intérêt à déclarer.

Anatomy and biomechanics of healthy and arthritic trapeziometacarpal joints

Anatomie et biomécanique de l'articulation trapézo-métacarpienne saine et arthrosique

Abstract

Understanding the biomechanics of the trapeziometacarpal (TMC) or first carpometacarpal (CMC1) joint, the pathophysiology of basal thumb arthritis, the design and performance of surgical procedures require a solid anatomical basis. This review of literature summarizes the most recent data on the descriptive, functional, and comparative anatomy of healthy and arthritic TMC joints.

Résumé

La compréhension de la biomécanique de l'articulation trapézo-métacarpienne (ATMC), de la physiopathologie de la rhizarthrose, la conception et la réalisation des gestes chirurgicaux nécessitent de solides bases anatomiques. Cette revue de la littérature synthétise les données les plus récentes concernant l'anatomie descriptive, fonctionnelle et comparée de l'ATMC saine et arthrosique.

Keywords: Anatomy; Biomechanics; Trapeziometacarpal joint; 1st carpometacarpal joint; Osteoarthritis

Mots-clés: Anatomie ; Biomécanique ; Articulation trapézo-métacarpienne ; 1^{ère} articulation carpo-métacarpienne ; Rhizarthrose

1. Introduction

The trapeziometacarpal (TMC) or first carpometacarpal (CMC1) or basal thumb joint is crucial to providing the thumb with its large range of motion. This is particularly true when an arthrodesis has been performed at the more distal joints to address inflammatory, degenerative, or post-traumatic conditions. It is affected in basal joint arthritis for reasons that are still not well understood. Knowledge of its anatomy and biomechanics is essential to understanding the pathophysiology of basal joint arthritis and to designing surgical procedures.

The following topics will be reviewed:

- the thumb's role in the hand and thumb movements
- the normal TMC joint
- the arthritic TMC joint
- the operated TMC joint
- the TMC joint in an evolutionary context.

2. The thumb: its role in the hand and its movements

The thumb is the shortest of our digits. Its skeleton consists of two carpal bones (scaphoid and trapezium), the first metacarpal and only two phalanges (proximal and distal). These bones are articulated by four joints: 1) scaphotrapezial, anterolateral portion of the scaphotrapeziotrapezoid (STT) joint, 2) TMC, 3) metacarpophalangeal (MCP) and 4) interphalangeal (IP).

To be able to be opposed to the other fingers, while also being able to flatten the hand on a hard surface, the thumb is not located in the same plane as the other fingers. At rest, it makes an angle of nearly 45° open laterally in the frontal plane and of nearly 30° open anteriorly in the sagittal plane with the longitudinal axis of the forearm prolonged by the axis of the middle finger.

Before we look at the ligaments and muscles, it is important to define the basic movements the thumb can make. We will adopt the terms typically used in the anatomical

and clinical context [1], although engineers who perform biomechanical studies use Euler angles, which are harder for clinicians to grasp [2].

The movements of *antepulsion* and *retropulsion* occur at the TMC joint in the sagittal plane. They are defined relative to the plane of the palm, considered as the frontal reference plane. Antepulsion (or anteposition) bring the thumb in front of the plane of the palm. Retropulsion (or retroposition) brings the thumb behind this plane. These movements occur around an axis passing through the trapezium [3], which is angled anteriorly, laterally, and proximally (Fig. 1). Their mean amplitude of 53° ranges between 50° and 90° [4].

The movements of *abduction* and *adduction* occur at the TMC joint in the frontal plane (that of the palm). Abduction spreads the thumb away from the second metacarpal while adduction brings it closer. These movements occur around an axis passing through the base of the first metacarpal [3], which is angled anteriorly, medially, and slightly distally (Fig. 1). Their mean amplitude has been measured at 42° [4], 51° [5], and up to 76° [6].

The movements of *flexion* and *extension* occur in the thumb's longitudinal plane, angled about 45° relative to the frontal plane and 30° relative to the sagittal plane; it involves the thumb's three main joints. Flexion brings the tip of the thumb towards the palm, while extension moves it away. Their mean amplitude is between 40 and 45 degrees: 41° [5], 43° [6].

The movements of *pronation* and *supination* occur along the longitudinal axis of the bones. Relative to the plane of the thumb's tip, we can distinguish between pronation, which turns the tip so that it opposes itself to the tips of the other fingers (internal rotation) and supination, which turns the thumb's tip in the other direction (external rotation). These movements are a continuation of those of the forearm. Their mean amplitude is between 15 and 25 degrees: 17° [4], 21° [5], 23° [6].

Next, *opposition* is the ability to bring the thumb's tip into contact with the tip of one of the other four fingers to create a pinch grip (from the Latin *pollex*, *pollicis*, which means thumb). Opposition has four elements: antepulsion and adduction, which mainly occur in the TMC joint; flexion, which mainly occurs in the MCP joint; pronation whose amplitude

decreases from the base of the thumb to its distal tip (60° in the TMC, 23° in the MCP, 7° in the IP [7]). During a clinical examination, opposition is evaluated with the Kapandji score [8]. Now, *counteropposition* is the reverse movement; it can also be evaluated with the Kapandji score [8].

Next is *apoposition* (apo = spread way) has been described as the position in which the TMC is completely abducted and supinated, while one or both of the thumb's distal articulations are flexed. Apoposition is the thumb position required for writing [9].

All these basic movements are combined to achieve *circumduction*: flexion-extension of 27°, adduction-abduction of 37° and pronation-supination of 10° [10]. It occurs around a middle circumduction center located at the center of the trapezial articular surface [11]. It allows the tip of the thumb to move in space by an average of 103 mm in abduction-adduction and 131 mm in flexion-extension; however, in common gestures, only two-thirds of this range is used (67 and 73 mm, respectively) [12].

The amplitude of all these movements varies greatly in the general population and is influenced by age and sex [13]. It is similar in the dominant or non-dominant hand, in women or men [14].

The "reference position" of the first metacarpal, in which the reference axes of the trapezium and first metacarpal are aligned, entails 48° of antepulsion, 38° of abduction and 80° of pronation relative to the axis of the third metacarpal [4].

3. The normal trapeziometacarpal joint

3.1. Bones

The trapezium has six faces (Fig. 2):

- the palmar face has a groove for the flexor carpi radialis (FCR) tendon, which is delimited anteriorly and laterally by the tubercle of trapezium
- the dorsal face has a tubercle on which the dorsal ligaments insert
- the proximal face articulates with the distal pole of the scaphoid

- the distal face articulates with the base of the first metacarpal; its slope in the frontal plane can be measured relative to the axis of the second metacarpal; this is the “dévers” or slope angle [15]
- the rougher lateral face is the site where the muscles of the thenar compartment insert
- the medial face is divided into two distinct articular surfaces, one for the trapezoid proximally and one for the second metacarpal distally [16].

The first metacarpal is the shortest of all the metacarpals. A cross-section of its canal reveals a trapezoidal medial boundary and a triangular lateral boundary. The design of metacarpal stems for TMC prostheses must take this into account.

3.2. Joints

The TMC is a saddle joint (or articulation by reciprocal reception), which opposes the distal surface of the trapezium to the base of the first metacarpal. Nevertheless, few joint replacement prostheses have been able to reproduce this dual saddle configuration, thus most function as a ball-and-socket joint.

3.2.1. Articular surfaces

The trapezium has a concave surface from front to back and a convex one from inside to outside. Its ridge guides flexion-extension movements. It is curved, not straight (like a road going over a col [1] or like the vertebral column of a scoliotic horse). For this reason, pronation always occurs with some flexion, while supination always occurs with some extension.

The articular surface of the first metacarpal is larger than that of the trapezium, convex from front to back and concave from inside to outside. Its ridge guides the antepulsion and retropulsion movements. In front, it terminates as a bone beak, which gave rise to the name “beak ligament”. The magnitude of the slope is not something that we currently measure, but it contributes to poor outcomes after arthroplasty [17].

These two surfaces are not fully congruent; thus, it is not possible to characterize them by two unique radiuses of curvature and by an angle between two asymptotes [18].

3.2.2. Capsule and ligaments

These soft tissue elements are responsible for the passive stability of the TMC joint. Several descriptions of the ligaments around the TMC joint exist. Although it has some inaccuracies, the most used one is by Bettinger et al. [19,20]. Among the 16 ligaments, the main ones are (Fig. 3):

- The anterior oblique ligament (AOL) has two parts, a superficial one (sAOL) and a deep one (dAOL); the deep part is intra-articular and is often referred to as the "beak ligament". This ligament is taut in abduction, extension, and pronation – which it limits – while it is relaxed when the thumb is in retropulsion. Its thickness measured by ultrasonography varies between its metacarpal insertion (0.7 mm), its middle portion (0.98 mm) and its trapezial insertion (0.65 mm). Its static length actually differs between the dominant hand (10.6 mm) and the non-dominant hand (9.6 mm) [21]. Measurements taken on MRI images are less precise (thickness typically less than 2.2 mm) [22].
- The intermetacarpal ligament (IML) has a "Y" configuration. The two arms of the Y insert on the base of the second metacarpal while its common trunk inserts on the first metacarpal: the dorsal intermetacarpal ligament (DIML or dorsal first MC ulnar base-second MC radial base intermetacarpal ligament [23]) and the volar intermetacarpal ligament (VIML or volar first MC ulnar base-second MC radial base intermetacarpal ligament [23]). It is taut in abduction, which it constrains [9]. Its thickness on MRI images is 3 mm (2.9–3.1 mm) [22]. This ligament is reconstructed during trapeziectomy procedures to prevent proximal migration of the first metacarpal.
- The dorsoradial ligament (DRL) extends between the dorsal tubercle of the trapezium and the base of the first metacarpal. It is taut in abduction and flexion,

relaxed in antepulsion and opposition [24]; it constrains abduction. It is an important stabilizer of the TMC joint because it counters the forces directed dorsally and it is rich in proprioceptors. Based on MRI, its thickness is 1.2–1.4 mm [22].

- The posterior oblique ligament (POL) is taut in extension and relaxed in retropulsion, while it constrains supination.
- The ulnar collateral ligament (UCL) has also been called the medial collateral ligament by Kuhlmann and Guérin-Surville [25]. It inserts on the medial tubercle of the metacarpal, near the distal center of rotation, but further away from the proximal center of rotation. It is more superficial and more ulnar than the AOL. The movements made around the distal center do not involve any pronation-supination, while the movements occurring around the proximal center are necessarily accompanied by pronation or supination [25].

The stabilizing components of the trapezium can be added to this:

- The volar and dorsal **trapezio**-trapezoidal ligaments, the ligaments spanning between the trapezium and second metacarpal, volar and dorsal (DT-IITM), and the ligament spanning between the trapezium and third metacarpal (TIII-MC) appear to function as stays to combat the moment arms acting on the trapezium from the first metacarpal. In this complex, the TIII-MC ligament appears to be the most important stabilizer of the trapezium [26].
- Added to this are the palmar scaphotrapezial ligament, radial scaphotrapezial ligament and the trapezoidal-capitate ligament.

In addition to these main ligaments, Ladd et al. identified a central dorsal ligament [27]. Kuhlmann identified an anteromedial ligament, part of the posteromedial ligament complex, named the retinaculometacarpal ligament due to its proximal insertion, which plays a key role in the suspension and anchoring of the base of the first metacarpal. It induces slight translation of the metacarpal along the concave articular surface of the trapezium during lateral pinch grips and pronation-supination of 90° [28].

193 The appearance and location of the dorsal ligaments (DTM, POL, DCL and DRL) are
194 consistent during arthroscopy, but those of the palmar ligaments (sAOL, dAOL and UCL)
195 vary greatly: the sAOL resembles a thin veil of membranous tissue that is draped in a
196 variable manner on the anterior portion of the joint capsule. What is known as the AOL and
197 UCL appears to correspond solely to a thicker portion of this veil around the volar beak,
198 although these ligaments cannot always be identified during macroscopic dissection [29].

199 Initially, several authors [19,30,31] claimed that the AOL, with its two layers
200 (especially the dAOL) was the thicker and mechanically more important one, although it is
201 located on the same side as the powerful thenar muscles and consider it to be the main
202 stabilizer of the TMC joint. All these authors believe that the IML, UCL and POL are only
203 secondary stabilizers, which fuse to form an assemblage nucleus at the base of the first
204 metacarpal.

205 According to Imaeda et al., the DRL does not appear to play either a primary or
206 secondary role in stabilizing the thumb [11,32]. But many subsequent studies
207 [27,33,34,35,36,37,38,39,40,41] showed that the DRL was in fact shorter, thicker, less
208 extendible, stiffer, and richer in mechanoreceptors than the AOL. Thus, it appears to be the
209 main obstacle to dorsoradial subluxation. When it is transected in experimental studies, it
210 causes the most amount of dorsoradial subluxation of the first metacarpal [35,42].

211 Similarly, in histology studies, the dorsal ligaments are significantly thicker and more
212 robust than the palmar ligaments, with more cells and more sensory innervation than the
213 AOL. The AOL is a thin structure that has the histological appearance of a low cellularity
214 capsular tissue instead of a true ligament; its location and insertions vary [27].

215 The dorsal ligaments (DRL, DCL and POL) have significantly more nerve endings
216 than the palmar ligaments (AOL and UCL) [38,43]. Most of the nerve endings are near the
217 bone insertions. Ruffini corpuscles are the predominant type of mechanoreceptor, with a
218 higher density in the metacarpal portion of each ligament. Along with their biomechanical
219 contribution to TMC stability, their presence suggests that these ligaments have a
220 proprioceptive function [38].

According to Comtet et al, the intermetacarpal ligaments (26%) and the AOL (39%) are subjected to the highest loads during thumb movements in the posteromedial and posterolateral directions, while the DRL and POL are subjected to lower loads (12%) in the other directions (anteromedial, medial, anterolateral, and maximum anteposition) [33].

3.2.3. Adjacent joints

Proximally, the STT joint is a planar articulation. It contributes to the thumb's mobility, as shown by D'Agostino et al., in flexion, adduction and especially in rotation [44,45].

Distally, the MCP joint is theoretically an ellipsoid (condylar) joint with two degrees of freedom: flexion-extension and radial and ulnar deviation. However, the two sesamoid bones and two powerful collateral ligaments limit its mobility in ulnar and radial deviation to favor stability. Consequently, the thumb MCP joint functions like a joint with a single degree of freedom. The metacarpal head is asymmetric: of its two palmar tubercles, the radial one is the largest; in 25-30° of flexion, it articulates with a hollow in the base of the proximal phalanx; when the UCL is under tension, this contributes to limiting abduction and external rotation [9]. The mean flexion amplitude is 56° [46] or 77° [47], depending on the shape of the metacarpal head: up to 70° flexion can occur if the head is round, but less than 40° if the head is flat [47]. The functional mobility ranges from 10° flexion deformity to 2° flexion according to Hume et al. [46] or 7.5° of flexion deformity to 5° flexion according to Murai et al. [48].

More distally, the IP joint is a hinge joint with a single degree of freedom associated with automatic rotation: flexion-pronation to one side and extension-supination to the other. Here again, the head of the phalanx is asymmetric: its radial lip is larger than its ulnar one; when the UCL is under tension, this contributes to limiting abduction [9]. The IP is used during all gestures of day-to-day living [49].

3.3. Muscles

The muscles are responsible for active stabilization of the TMC joint. The thumb appears imbalanced since there are four extrinsic muscles (including three on the dorsal side) and five intrinsic muscles (all located on the palmar side).

The following are the long or extrinsic muscles:

- The abductor pollicis longus (APL) is a complex muscle with deep and superficial parts [50]. The deep part has the larger muscle body and inserts around the TMC joint. The superficial part and every component of the deep part receive a different nerve branch than the deep branch of the radial nerve destined to the APL. It has a single tendon in only 5% of cases [51]. Most often it is formed of two to six tendons distributed into two groups (Fig. 4): a lateral one ending on the base of the first metacarpal and a medial one inserting either on the base of the first metacarpal (80% on anterolateral face and 20% on lateral face), on the trapezium (70-80%), the APB (60%), the thenar fascia (40–42%), the TMC joint capsule (30%) or the opponens pollicis (20%) [51,52]. The capsular insertions may reinforce certain ligaments [53]. It is mainly an abductor while also being an extensor of the TMC joint [54]; the superficial portion is said to work with the extensor pollicis brevis (EPB). Several anatomical studies have found no correlation between the severity of osteoarthritis and the types of distal APL insertions [51,55,56,57].
- The EPB is mainly an extensor, but also a weak abductor of the TMC joint [54,58,59,60].
- The extensor pollicis longus (EPL) is both an extensor and an adductor of the TMC joint [54] acting simultaneously and in a coordinated manner on the IP and MCP joints [61].
- The flexor pollicis longus (FPL) is a pure flexor [53], acting simultaneously and in a coordinated manner on the IP and MCP joints [61].

The APL, EPB and EPL have a combined extension and supination action on the TMC joint [61].

The short or intrinsic muscles are arranged in two layers, differentiated by their position relative to the tendon of the FPL and their innervation:

- The superficial thenar muscles are innervated by the recurrent branch of the median nerve and are located in front of the FPL tendon.
 - o The abductor pollicis brevis (APB) is responsible for flexion, antepulsion and pronation (but not abduction, more likely adduction [54]) of the TMC joint. It contracts at the same time as the APL during many thumb movements, acting as a stabilizer.
 - o The opponens pollicis is the only muscle that terminates on the first metacarpal; it is responsible for flexion, antepulsion, and pronation of the TMC joint, along with abduction [54].
 - o The superficial head of the flexor pollicis brevis (FPB)
- The deep thenar muscles are innervated by the deep branch of the ulnar nerve and are located behind the FPL tendon:
 - o The deep head of the flexor pollicis brevis (FPB)
 - o The adductor pollicis is responsible for adduction, retropulsion and supination of the TMC joint, along with flexion [54]; it has two heads, transverse and oblique.
- The first dorsal interosseous muscle also acts on the TMC joint; it has also been called the lateral **thenar** muscle. When it contracts, it reduces the subluxation of a healthy TMC joint [62]. This muscle causes the least dorsoradial translation and causes the most distal translation of the metacarpal base [63]. For this reason, there is an emphasis placed on this specific muscle during the rehabilitation for thumb basal joint arthritis.

The APL and adductor pollicis form a destabilizing functional pair, responsible for the abduction and dorsolateral subluxation of the first metacarpal (APL) and closure of the first web, which is made worse by all the other intrinsic muscles.

Based on their position relative to the main axis of the TMC joint, we can differentiate:

- antepulsion muscles: FPL, APB, opponens pollicis and superficial head of the FPB
- retropulsion muscles: EPL, EPB, first dorsal interosseous
- abduction muscles: APL
- adduction muscles: adductor pollicis, deep head of FPB, first dorsal interosseous.

When we look at the thumb's overall movements, the FPL is the primary driver of isometric flexion; the EPL and APL are the primary drivers of isometric extension, the adductor pollicis and EPL are the primary drivers of isometric adduction; the APB and opponens pollicis are the primary drivers of isometric abduction [64]. During pinching and power gripping, the adductor pollicis and the FPL have the same electrical activity, with secondary contributions from the first dorsal interosseous and EPL. During key pinch, power grip and jar opening, the muscle recruitment is specific to each person but varies little from one task to another. The thumb's extrinsic muscles are significantly more active than the intrinsic muscles during these three tasks [65].

When the intrinsic muscles are absent, the action of the EPL and FPL tendons alone tends to extend the TMC joint when it is not stabilized, to extend the MCP when it is stabilized, and to flex the IP joint [66].

3.4. Vascularization

The arteries of the TMC joint come from the radial artery and its branch, the main artery of the thumb. They form a vascular network around the joint, which is denser on the dorsoradial side of the joint [67]. It is essential to be aware of its vascularization and to preserve it when doing peritrapezial osteotomies [68].

3.5. Innervation and the basis for denervation

The TMC is innervated by the radial and median nerves. The branches of the median nerve are more numerous and larger; they come from the palmar branch (11/15) and the recurrent branch by following a retrograde arcuate path between the APB and the opponens pollicis

(13/15), and sometimes directly from the median nerve in the carpal tunnel (5/15). The participation of the lateral cutaneous nerve of the forearm and the superficial branch of the radial nerve is more modest [69]. According to Loréa, the thenar branch is divided into at least two main branches, one for the opponens pollicis and the other for the APB. Very often, the branch for the opponens pollicis courses over or inside its medial face to spread out on the palmar face of the trapezium [70,71]. The superficial branch of the radial nerve does not have an exclusive or dominating role in the TMC joint's innervation [72]. The deep branch of the ulnar nerve also innervates the TMC, which could explain some of the potential failures of denervation [73].

According to Loréa et al., two incisions are needed to transect all the articular branches coming from the superficial branch of the radial nerve, the palmar cutaneous branch of the median nerve, the recurrent branch of the median nerve and the lateral cutaneous nerve of the forearm [69,74].

3.6. Anatomical relationships

The radial artery is 4 or 5 mm proximal to the dorsal arthroscopic portal, following a course 4–8 mm from the joint space and 8–11 mm from the EPB. Some of the sensory branches coming from the dorsal branch of the radial nerve are close to the dorsal surgical approach. According to Espinosa Gutiérrez et al., there is a safe zone for the dorsal arthroscopy portal between the EPL and EPB [75].

3.7. Biomechanics

3.7.1. Stability

The contact area is the greatest during palmar abduction and the least in adduction [10]. When centered, the contact surfaces are reduced [76]. Their span is minimal, a bit less on the trapezium than the base of the first metacarpal [77]. The location and breadth of the contact areas vary by the type of movement done [78]:

- latero-palmar on the trapezium and lateral on the first metacarpal in opposition, representing 53% of the articular surfaces [78] with a stress concentration on this zone during power gripping [77]
- lateral (radial) on the trapezium and the first metacarpal in palmar abduction, representing 28% of the articular surfaces [78]
- dorsal on the trapezium and the first metacarpal in radial abduction, representing 25% of the articular surfaces [78]
- central palmar for the trapezium and first metacarpal during circumduction, except in adduction [10].

In the study by Ateshian et al. [79], key pinch was responsible for contact areas primarily in the central, palmar, and ulnar portions of the trapezium and metacarpal. The TMC remains stable during key pinch, jar grasp and jar twist, with no difference between sexes [80].

3.7.2. Loads

A famous study by Cooney and Chao [81] showed that the extrinsic and intrinsic tendons supported loads of up to 10 and 30 kg, respectively, during a pinch grip, producing a 5 kg load at the tip of the thumb and that tendon forces reached 50 kg during power grip. The compression loads were calculated to be 3 kg at the IP joint, 5.4 kg at the MCP joint and 12 kg at the TMC joint during a pinch grip generating 1 kg (Fig. 5). They could reach 120 kg during a power grip.

3.7.3. Resting position

At rest, the TMC has a slight subluxation dorsally (1.8–2.0 mm) and radially (2.8–3.4 mm) [22].

3.7.4. Mobility

According to Zancolli et al., the TMC is shaped to allow isolated angular movements but also associated angular and rotational movements of the first metacarpal. To accomplish

this, the geometry of the joint is compartmentalized: one section has a saddle shape (central zone of the trapezial surface and metacarpal crest) where the simpler angular movements occur, while another section has a spheroid shape (palmar portion of the trapezial articular surface and the slopes of the metacarpal surfaces) where combined movements occur [82].

The two main axes of the TMC are in non-orthogonal and non-secant planes [83], which differ from the anatomical reference planes and explains why complex movements do not occur in the classical reference planes (frontal or sagittal) but in planes that are oblique to these reference planes. The flexion-extension axis passes through the trapezium while the abduction-adduction axis passes through the first metacarpal [11,84]. Thus flexion-extension and abduction-adduction movements are coupled with automatic internal and external rotation movements along with translation movements: internal rotation and ulnar translation is coupled with flexion, implying a screw-like stabilization mechanism [44,84]. The base and head of the first metacarpal shift in the same direction during flexion-extension but in opposite directions during abduction-adduction [11].

During flexion, all the ligaments are placed under tension, except for the beak ligament which becomes slack. During adduction and opposition, the POP and DIM are placed under tension, while the DRL and beak ligament slacken [37].

Axial rotation of the TMC mainly occurs when the hand is used during a cylindrical or spherical grip [49]. Axial rotation is controlled by muscles; when the joint is compressed, there is not more than 3° motion [18]. During opposition, the flexion and pronation movements are coupled [7].

3.8. Sex-related variations

Unsurprisingly, the bones in women are smaller than those in men, thus the articular surfaces are also. There is no difference in the width of the TMC joint space between young men and young women [24], nor any differences in joint congruency [85] or kinematics [80]. According to Schneider et al. [86], there is no difference in the shape of the metacarpal surface between men and women. According to Ateshian et al. [87], the congruency is not as

good in women as it is in men: the concavity of the metacarpal surface and the convexity of the trapezial surface are less pronounced in women than in men [88,89].

4. The arthritic trapeziometacarpal joint

Basal joint arthritis is attributed to TMC instability/hypermobility, which is visible on stress X-ray images [90] allowing lateral translation of the metacarpal on the trapezium [30,91,92]; however, this was contradicted by the study of Kraus et al. [93]. Lesions identical to the ones seen in osteoarthritis were simulated by transecting the beak ligament [94].

4.1. Incidence of basal joint arthritis by age and sex and combination with other types of arthritis

In a British study, symptomatic clinical and radiological basal joint arthritis affects 2.2% of the population and isolated erosive finger osteoarthritis is found in 0.5%, although these two conditions are very often present at the same time [95]. In a Swedish study, basal joint arthritis was the reason for consultation with a general practitioner in 1.4% of patients over 20 years of age (2.2% in women and 0.6% in men). The mean age at the time of consultation was 68 years, although women were seen at a younger age than men by about 10 years [96]. In post-menopausal women, the prevalence of isolated TMC arthritis, STT arthritis and **peritrapezial** TMC+STT arthritis was 25%, 2% and 8%, respectively. Only 28% of cases of isolated TMC arthritis and 55% of TMC + STT osteoarthritis were symptomatic [97]. In a cadaver study with 69 specimens, severe concurrent osteoarthritis was found in the TMC and STT joints of 60% of specimens. There was a correlation between the severity of the TMC arthritis and that of STT arthritis. Radiographic and macroscopic changes in the STT joint were visible in 39% of subjects [98]. Similarly, the presence of STT arthritis is highly correlated with the presence of TMC arthritis [99].

In a cohort of 36 fresh cadaver TMC joints, Maes-Clavier et al. found that 17 joints (71% men) were stage I (no osteoarthritis) to stage III (moderate osteoarthritis) while 19 joints (95% women) were stage IV (major cartilage damage) [100].

443

444 4.2. Macroscopic changes in the trapeziometacarpal joint due to basal joint arthritis

445 Unsurprisingly, basal joint arthritis leads to narrowing of the joint space [24,88], changes in
446 joint congruency [85] and loss of trapezial height.

447 The cartilage in an arthritic TMC joint is said to be thinner by 0.8 ± 0.2 mm for the
448 trapezium and 0.7 ± 0.2 mm for the metacarpal. This affects the radial sides of the
449 metacarpal initially, progressing towards the palmar sides and the dorsoradial side of the
450 trapezium, progressing towards the palmar sides [88,89].

451 Degenerative lesions are mainly observed in the zones loaded during joint
452 movements, especially opposition [100]: on the radial, palmar, and ulnar facets of the
453 trapezium [78,84,101], and the dorsal and palmar facets [84] and ulnar facet [101] of the
454 metacarpal. The arthritic changes are less severe on the dorso-ulnar portion of the trapezium
455 and the dorsal portion of the metacarpal, known to be the less-loaded regions [102]. As the
456 arthritis worsens, the concavity of the trapezium become deeper while its convexity becomes
457 flatter whereas the metacarpal's concavity flattens, and its convexity increases [103,104];
458 these changes are more apparent in women than in men [89]. This results in an increase in
459 the joint congruency, although it is less in women than in men [105]. The average ratio
460 between the dorso-palmar diameter and the transverse diameter of the metacarpal
461 articulating surface increases. Lengthening of the articular surface [100] in the dorso-palmar
462 direction is related to the presence of a palmar osteophyte.

463 The trapezium loses proximo-distal thickness (22% according to Nufer et al. [106]),
464 but as a reaction to the increased stresses, the thickness of the subchondral bone increases
465 by 50%, and the bone volume increases 42% because of an increase in the number (10%),
466 thickness (18%) and connectivity of the bone trabeculae [106,107]. These modifications are
467 more apparent in the dorsoradial part of the joint [102,108]. The women in their study with
468 confirmed osteoarthritis had a more pronounced radio-ulnar incurvation than the men with
469 osteoarthritis [108]. The wear is asymmetric, resulting in an increase in the trapezial slope:

42° ± 4° for hands without arthritis or with Eaton stage I or II arthritis, 50° ± 4° for hands with Eaton stage III and IV arthritis [20].

Despite the joint space narrowing, the mean distance between the ligament insertions and the metacarpal articular surface remains greater than 2 mm, except for the metacarpal insertion of the DRL [100]. There are also soft tissue lesions that affect only the metacarpal insertion of the beak ligament [109]: degeneration of its metacarpal insertion was observed during palmar chondromalacia with complete detachment when the surfaces are eburnated [110]. The mechanical properties (resistance to stretching) of the main ligaments decrease [34] in a directly correlated manner with the condition of the TMC cartilage and with age. Slackening of the ligaments alters the mechanical balance of the musculotendinous stays, especially the APL and EPB, which may contribute to the joint deformities observed in basal joint arthritis [111].

The centers of rotation of flexion-extension are translated more dorsally in the patient group, while the centers of rotation during abduction-adduction are not altered [112,113].

Basal joint arthritis is also accompanied by changes in the function of the thumb's intrinsic muscles [114]: loss of APB effectiveness secondary to changes in its vector, loss of electrical activity and 50% loss in the cross-section area of the superficial portion of the FPB.

4.3. Ethnic variations

The frequency and distribution of idiopathic basal joint arthritis varies greatly among different ethnic groups according to a study done on 61 Asian and 100 Caucasian cadavers [110]. Among the 35 Japanese cadavers, 23 (66%) had completely normal articular surfaces, 5 (14%) had chondromalacia limited to the dorsal part of the articular surfaces, 2 (6%) had chondromalacia in the palmar portion of the articular surfaces and five (14%) had visible subchondral bone with advanced degenerative lesions. A similar distribution was found in the 22 Chinese cadavers. When it was present, osteoarthritis had the same features as those observed in Caucasians. The concave-convex configuration of the articular surfaces was flatter in Asians than in Caucasians. In the latter, only 25% had normal articular surfaces,

10% had dorsal chondromalacia considered as being age-related, 15% had palmar chondromalacia considered as being pre-arthritic, while 50% had visible subchondral bone with advanced arthritis.

4.4. Microscopic and biological changes in basal joint arthritis

Biochemically, the palmar articular surfaces affected by chondromalacia are characterized by a loss of glycosaminoglycans, retention of collagen, and shift in the sub-species of glycosaminoglycans, as evidenced by the increased chondroitin sulfate/keratan sulfate ratio. This contrasts with the dorsal articular surface that biochemically resemble the normal surfaces of the trapezium's articular facets for the scaphoid and trapezoid [115].

Histologically, the earliest changes are seen in the tangential surface layer and occur in the areas of chondromalacia in the volar portion of the contact areas. Progressive disruption of this superficial fibrillar layer of the articular cartilage is followed by disorganization of the chondrocytes and underlying matrix. In the palmar portion where the chondromalacia lesions are more advanced, we observe a loss of eosinophilic staining, free cellular elements, and craters 20–30 mm in diameter resembling empty chondrocytic lacuna, and an absence of any meshing of the tangential surface. In the eburnated zones where the sub-chondral bone is visible, there are no cellular nor fibrillar elements. The disruption of the protective layer of articular cartilage occurs in a spatial configuration corresponding to the contact zones where selective decomposition of the proteoglycan matrix has been observed [115]. The water content increases, the proteoglycan content decreases and the collagen content relative to dry weight does not change. Concurrently, the compression stiffness and the permeability decrease, contrary to what has been observed in the hip and knee [116].

The collagen fibers of the beak ligament are disorganized at their metacarpal insertion. The normal fibrocartilage insertion zone is often not identifiable on the metacarpal side, and in cases of more advanced arthritis, a synovial recess appears across from the palmar beak of the metacarpal. The trapezial insertion of the beak ligament has no degenerative alterations. Severe cartilage lesions are associated with progressive and

selective degeneration of the collagen network of the beak ligament at its metacarpal insertion [109].

The decrease in ligament strength may be due to relaxin, a peptide hormone that relaxes ligaments before a woman gives birth, by the intermediary of remodeling of the extracellular matrix via the regulation of matrix metalloproteases acting on the relaxin/insulin-like family peptide receptors 1 (RXFP-1). These are receptors for circulating relaxin, which are present in ligaments, cartilage, and the synovial membrane, and in higher concentrations in basal joint arthritis [117]. The DRL preserves a dense collagen organization, evidence of its effectiveness, while the AOL is made of disorganized connective tissue that is low in collagen and low in mechanoreceptors [42].

4.5. Consequences of anatomical lesions on function

Basal joint arthritis is accompanied by a reduction in TMC mobility. Stage II/III basal joint arthritis restricts mobility in abduction-adduction (38° in control subjects, 26° in basal joint arthritis) without restricting flexion-extension or pronation-supination. It also reduces MCP mobility in abduction-adduction by 48% (32° in control subjects, 16° in basal joint arthritis) and in pronation-supination by 42% (34° in control subjects, 20° in basal joint arthritis) [14]. In stages III and IV, relative to a healthy population, the mobility was reduced by 14° in flexion-extension (mainly on the extension side), by 26° in abduction-adduction (mainly on the abduction arc), and by 13° in pronation-supination [118]. This TMC stiffness generates compensatory mobility of the trapezium in abduction [113] and requires greater force generation by the muscles and tendons to move it, especially the FPL and EPL, which may explain the difference observed between passive and active mobility [119].

Early basal joint arthritis is accompanied by reduced strength in pinch grips, more apparent in key pinch than in tip-to-tip or tripod pinch [120], but also in cylindrical grips [121], in thumb abduction and index finger extension [122]. This measurable strength loss is correlated with the clinical impact (DASH score), especially that of tip-to-tip pinch [123] and

can thus serve as an objective evaluation of the functional impact. In the presence of arthritis in other fingers, the strength loss is specifically related to the condition of the thumb [124].

During three functional isometric tasks (gripping a key, holding a jar, and opening a jar) in 76 patients with early basal joint arthritis, the TMC was more unstable during key pinch than during the other two tasks. Sex, age, and early arthritis had no effect on TMC instability, suggesting that instability during these three tasks does not predispose one to arthritis [125].

4.6. Potential for spontaneous healing

Lovati et al. found better chondrogenic potential in femoral chondrocytes than in trapezial ones. They concluded that the trapezium had a lower regenerative capacity than the femoral head [126].

4.7. Consequences of thumb basal joint arthritis on the MCP joint

As the adductus of the first metacarpal worsens, the MCP joint develops hyperextension that allows large objects to be manipulated despite the closure of the first web. This hyperextension appears more likely to develop when the metacarpal head is rounded (as opposed to flat) and the first metacarpal is short, whether congenital or related to basal joint arthritis (joint narrowing, trapezium collapse, subluxation, disappearance of the palmar beak after AOL release) [127]. Hypermobility of the MCP may play a causal role in the development of primary basal joint arthritis by concentrating the loads on the palmar part of the joint, since MCP flexion unloads the most palmar part of the TMC articular surfaces, no matter the severity of the basal joint arthritis [128].

5. The operated trapeziometacarpal joint

5.1. Trapeziectomy

According to Goubier et al., after trapeziectomy with ligament reconstruction, the TMC motion is 50° during flexion-extension, 47° during abduction-adduction and 11° during axial rotation. There is no significant difference with the motion of healthy joints, except for

circumduction that is reduced after surgery [5]. Koff et al. compared total trapeziectomy with and without LRTI, the Weilby arthroplasty and the Thomson arthroplasty. Motion was better after the Thomson arthroplasty and after LRTI, while trapeziectomy with LRTI yield results that were the closest to those of an intact thumb [129].

5.2. Arthroplasty with a prosthesis

Most of the prostheses available are spheroid, with three degrees of freedom, not saddle-shaped with two degrees of freedom. Under these conditions, the dislocating forces are 12 times greater [130].

This highlights how important the soft tissues are to stabilize non-retaining implants. Stabilization of spheroid implants is essentially passive and relies on 1) minimal bone cuts and the preservation or reconstruction of the main ligaments, 2) larger bone cuts and tensioning of periarticular soft tissues, 3) use of retaining or dual mobility implants. Dynamic muscular stabilization participates in passive stability; it appears to be the only mechanism to control pronation and supination.

These days, the metacarpal stem corresponds to the shape of the medullary canal. The orientation of the cup in the trapezium is more challenging. Duerinckx and Caekebeke have suggested that the cup must be placed parallel to the trapezium's proximal articular surface (the one that articulates with the scaphoid) and that it should be combined with a metacarpal neck having 7° offset, both to optimize mobility and to minimize the risks of postoperative complications [131].

Nevertheless, the prosthetic joint does not exactly reproduce the kinematics of the healthy TMC joint [112].

6. The trapeziometacarpal joint in an evolutionary context

The saddle shape of the TMC joint is not specific to modern Man, as it has also been found in hominin fossils [132]. A study of the radius of curvature of the articular surfaces confirms that Man (Homo) derives from large African apes (Gorilla, Pan), from the Australopithecus

609 afarensis and from the Neandertal man, with progressive flattening. The orang-outang
610 (Pongo) lies between Man and African apes. The baboon (Papio) has surfaces that are even
611 flatter than those of Man, which are cylindrical [133]. The TMC of Man has the same mobility
612 as those of the chimpanzee in all movements, including coupled movements, except for
613 extension which is greater in Man [134] and the muscular couples being greater due to
614 longer moment arms [135]. The other notable feature of the thumb's evolution is widening of
615 the distal phalanx [136].

616 **7. Conclusion**

617 Knowledge of descriptive, functional, and comparative anatomy is essential to the
618 understanding of the causes and consequences of basal joint arthritis, while knowledge of
619 vascularization, innervation, and relationships of the TMC joint are needed for its surgical
620 treatment.

References

1. Kapandji AI. Physiologie articulaire. Tome 1: membre supérieur (6^{ème} éd.). Paris ; Maloine: 2005.
2. Dumas R, Cheze L, Fayet M, Rumelhart C, Comtet JJ. [How to define the joint movements unambiguously: proposal of standardization for the trapeziometacarpal joint]. Chir Main 2008;27:195-201.
3. Hollister A, Buford WL, Myers LM, Giurintano DJ, Novick A. The axes of rotation of the thumb carpometacarpal joint. J Orthop Res 1992;10:454-60.
4. Cooney WP 3rd, Lucca MJ, Chao EY, Linscheid RL. The kinesiology of the thumb trapeziometacarpal joint. J Bone Joint Surg Am 1981;63:1371-81.
5. Goubier JN, Devun L, Mitton D, Lavaste F. In vivo kinematics of the first carpometacarpal joint after trapeziectomy. Chir Main 2011;30:97-101.
6. Chang LY, Pollard NS. Method for determining kinematic parameters of the in vivo thumb carpometacarpal joint. IEEE Trans Biomed Eng 2008;55:1897-906.
7. Li ZM, Tang J. Coordination of thumb joints during opposition. J Biomech 2007;40:502-10.
8. Kapandji A. Clinical test of apposition and counter-apposition of the thumb. Ann Chir Main 1986;5:67-73.
9. Bojsen-Moller F. Osteoligamentous guidance of the movements of the human thumb. Am J Anat 1976;147:71-80.
10. Goto A, Leng S, Sugamoto K, Cooney WP 3rd, Kakar S, Zhao K. In vivo pilot study evaluating the thumb carpometacarpal joint during circumduction. Clin Orthop Relat Res 2014;472:1106-13.
11. Imaeda T, Niebur G, An KN, Cooney WP 3rd. Kinematics of the trapeziometacarpal joint after sectioning of ligaments. J Orthop Res 1994;12:205-10.
12. Tang J, Zhang X, Li ZM. Operational and maximal workspace of the thumb. Ergonomics 2008;51:1109-18.

13. Kuo LC, Cooney WP 3rd, An KN, Lai KY, Wang SM, Su FC. Effects of age and gender on the movement workspace of the trapeziometacarpal joint. *Proc Inst Mech Eng H* 2009;223:133-42.
14. Hamann N, Heidemann J, Heinrich K, Wu H, Bleuel J, Gonska C, Brüggemann GP. Effect of carpometacarpal joint osteoarthritis, sex, and handedness on thumb in vivo kinematics. *J Hand Surg Am* 2014;39:2161-7.
15. Kapandji AI, Moatti E, Raab C. La radiographie spécifique de l'articulation trapézo-métacarpienne. Sa technique, son intérêt. *Ann Chir Main* 1980;34:719-26.
16. Humes D, Jähnich H, Rehm A, Compson JP. The osteology of the trapezium *J Hand Surg Br* 2004;29:42-5.
17. Tonogai I, Hamada Y, Hibino N. Evaluation of the first metacarpal proximal facet inclination as a prognostic predictor following arthroplasty for osteoarthritis of the thumb carpometacarpal joint. *Hand Surg* 2013;18:69-72.
18. Dathe H, Dumont C, Perplies R, Fanghänel J, Kubein-Meesenburg D, Nägerl H, Wachowski MM. The thumb carpometacarpal joint: curvature morphology of the articulating surfaces, mathematical description and mechanical functioning. *Acta Bioeng Biomech* 2016;18:103-10.
19. Bettinger PC, Linscheid RL, Berger RA, Cooney WP 3rd, An KN. An anatomic study of the stabilizing ligaments of the trapezium and trapeziometacarpal joint. *J Hand Surg Am* 1999;24:786-98.
20. Bettinger PC, Berger RA. Functional ligamentous anatomy of the trapezium and trapeziometacarpal joint (gross and arthroscopic). *Hand Clin* 2001;17:151-68, vii.
21. Chiavaras MM, Harish S, Oomen G, Popowich T, Wainman B, Bain JR. Sonography of the anterior oblique ligament of the trapeziometacarpal joint: a study of cadavers and asymptomatic volunteers. *AJR Am J Roentgenol* 2010;195:428-34.
22. Hirschmann A, Sutter R, Schweizer A, Pfirrmann CW. The carpometacarpal joint of the thumb: MR appearance in asymptomatic volunteers. *Skeletal Radiol* 2013;42:1105-12.

23. Nanno M, Buford WL Jr, Patterson RM, Andersen CR, Viegas SF. Three-dimensional analysis of the ligamentous attachments of the first carpometacarpal joint. *J Hand Surg Am* 2006;31:1160-70.
24. Halilaj E, Moore DC, Patel TK, Laidlaw DH, Ladd AL, Weiss AP, Crisco JJ. Older asymptomatic women exhibit patterns of thumb carpometacarpal joint space narrowing that precede changes associated with early osteoarthritis. *J Biomech* 2015;48:3634-40.
25. Kuhlmann JN, Guérin-Surville H. [Descriptive anatomy and biodynamic study of the medial collateral ligament of the trapezio-metacarpal articulation of the thumb]. *Bull Assoc Anat (Nancy)* 1985;69:315-30.
26. Bettinger PC, Smutz WP, Linscheid RL, Cooney WP 3rd, An KN. Material properties of the trapezial and trapeziometacarpal ligaments. *J Hand Surg Am* 2000;25:1085-95.
27. Ladd AL, Lee J, Hagert E. Macroscopic and microscopic analysis of the thumb carpometacarpal ligaments: a cadaveric study of ligament anatomy and histology. *J Bone Joint Surg Am* 2012;94:1468-77.
28. Kuhlmann JN. [Importance of the posteromedial trapeziometacarpal ligamentous complex]. *Chir Main* 2001;20:31-47.
29. Zhang AY, Van Nortwick S, Hagert E, Yao J, Ladd AL. Thumb carpometacarpal ligaments inside and out: a comparative study of arthroscopic and gross anatomy from the Robert A. Chase hand and upper limb center at Stanford university. *J Wrist Surg* 2013;2:55-62.
30. Pellegrini VD Jr. Osteoarthritis of the trapeziometacarpal joint: the pathophysiology of articular cartilage degeneration. II. Articular wear patterns in the osteoarthritic joint. *J Hand Surg Am* 1991;16:975-82.
31. McCann MR, Rust PA, Wallace R. The stabilizing effect of the anterior oblique ligament to prevent directional subluxation at the trapeziometacarpal joint of the thumb: a biomechanical cadaveric study. *Arch Bone Joint Surg* 2018;6:105-11.

32. Imaeda T, An KN, Cooney WP 3rd, Linscheid R. Anatomy of trapeziometacarpal ligaments. *J Hand Surg Am* 1993;18:226-31.
33. Comtet JJ, Rumelhart C, Chèze L, Fickry T. [The trapezio-metacarpal joint: the strain of the ligaments as a function of the thumb position. Study on an enlarged model]. *Chir Main* 2006;25:185-92.
34. Najima H, Oberlin C, Alnot JY, Cadot B. Anatomical and biomechanical studies of the pathogenesis of trapeziometacarpal degenerative arthritis. *J Hand Surg Br* 1997;22:183-8.
35. Van Brenk B, Richards RR, Mackay MB, Boynton EL. A biomechanical assessment of ligaments preventing dorsoradial subluxation of the trapeziometacarpal joint. *J Hand Surg Am* 1998;23:607-11.
36. Colman M, Mass DP, Draganich LF. Effects of the deep anterior oblique and dorsoradial ligaments on trapeziometacarpal joint stability. *J Hand Surg Am* 2007;32:310-7.
37. Tan J, Xu J, Xie RG, Deng AD, Tang JB. In vivo length and changes of ligaments stabilizing the thumb carpometacarpal joint. *J Hand Surg Am* 2011;36:420-7
38. Hagert E, Lee J, Ladd AL. Innervation patterns of thumb trapeziometacarpal joint ligaments. *J Hand Surg Am* 2012;37:706-14.e1.
39. D'Agostino P, Kerkhof FD, Shahabpour M, Moermans JP, Stockmans F, Vereecke EE. Comparison of the anatomical dimensions and mechanical properties of the dorsoradial and anterior oblique ligaments of the trapeziometacarpal joint. *J Hand Surg Am* 2014;39:1098-107.
40. Lin JD, Karl JW, Strauch RJ. Trapeziometacarpal joint stability: the evolving importance of the dorsal ligaments. *Clin Orthop Relat Res* 2014;472:1138-45.
41. Halilaj E, Rainbow MJ, Moore DC, Laidlaw DH, Weiss AP, Ladd AL, Crisco JJ. In vivo recruitment patterns in the anterior oblique and dorsoradial ligaments of the first carpometacarpal joint. *J Biomech* 2015 Jul 16;48:1893-8.

42. Esplugas M, Lluch-Bergada A, Mobargha N, Llusa-Perez M, Hagert E, Garcia-Elias M2. Trapeziometacarpal ligaments biomechanical study: implications in arthroscopy. J Wrist Surg 2016;5:277-83.
43. Mobargha N, Ludwig C, Ladd AL, Hagert E. Ultrastructure and innervation of thumb carpometacarpal ligaments in surgical patients with osteoarthritis. Clin Orthop Relat Res 2014;472:1146-54.
44. D'Agostino P, Dourthe B, Kerkhof F, Stockmans F, Vereecke EE. In vivo kinematics of the thumb during flexion and adduction motion: Evidence for a screw-home mechanism. J Orthop Res 2017;35:1556-64.
45. Kerkhof F, Brugman E, D'Agostino P, Dourthe B, van Lenthe G, Stockmans F, Jonkers I, Vereecke E.E. Quantifying thumb opposition kinematics using dynamic CT. J Biomech 2016; 49:1994-9.
46. Hume MC, Gellman H, McKellop H, Brumfield RH. Functional range of motion of the joints of the hand. J Hand Surg 1990;15:240-3.
47. Yoshida R, House HO, Patterson RM, Shah MA, Viegas SF. Motion and morphology of the thumb metacarpophalangeal joint. J Hand Surg 2003;28:753–7.
48. Murai T, Uchiyama S, Nakamura K, Ido Y, Hata Y, Kato H. Functional range of motion in the metacarpophalangeal joints of the hand measured by single axis electric goniometers. J Orthop Sci 2018;23:504-10.
49. Lin HT, Kuo LC, Liu HY, Wu WL, Su FC. The three-dimensional analysis of three thumb joints coordination in activities of daily living. Clin Biomech (Bristol, Avon) 2011;26:371-6.
50. van Oudenaarde E, Oostendorp R. Significance of the innervation pattern of the human abductor pollicis longus muscle. J Anat 1992;181:155-9.
51. Bouchlis G, Bhatia A, Asfazadourian H, Touam C, Vacher C, Oberlin C. Distal insertions of abductor pollicis longus muscle and arthritis of the first carpometacarpal joint in 104 dissections. Ann Chir Main Memb Super 1997;16:326-38.

52. El-Beshbishy RA, Abdel-Hamid GA. Variations of the abductor pollicis longus tendon: an anatomic study. *Folia Morphol (Warsz)* 2013;72:161-6.
53. Kauer JM. Functional anatomy of the carpometacarpal joint of the thumb. *Clin Orthop Relat Res* 1987;220:7-13.
54. Smutz WP, Kongsayreepong A, Hughes RE, Niebur G, Cooney WP, An KN. Mechanical advantage of the thumb muscles. *J Biomech* 1998;31:565-70.
55. Roh MS, Strauch RJ, Xu L, Rosenwasser MP, Pawluk RJ, Mow VC. Thenar insertion of abductor pollicis longus accessory tendons and thumb carpometacarpal osteoarthritis. *J Hand Surg Am* 2000;25:458-63.
56. Schulz CU, Anetzberger H, Pfahler M, Maier M, Refior HJ. The relation between primary osteoarthritis of the trapeziometacarpal joint and supernumerary slips of the abductor pollicis longus tendon. *J Hand Surg Br* 2002;27:238-41.
57. Roush TF, Aldridge JM, Berger RA, Rizzo M. No correlation between trapeziometacarpal arthritis and abductor pollicis longus insertion. *Clin Orthop Relat Res* 2005;434:138-42.
58. Jabir S, Lyall H, Iwuagwu FC. The extensor pollicis brevis: a review of its anatomy and variations. *Eplasty* 2013;13:e35.
59. Brunelli GA, Brunelli GR. Anatomy of the extensor pollicis brevis muscle. *J Hand Surg Br* 1992;17:267-9.
60. Kulshreshtha R, Patel S, Arya AP, Hall S, Compson JP. Variations of the extensor pollicis brevis tendon and its insertion: a study of 44 cadaveric hands. *J Hand Surg Eur* 2007; 32:550-3.
61. Li ZM, Tang J, Chakan M, Kaz R. Complex, multidimensional thumb movements generated by individual extrinsic muscles. *J Orthop Res* 2008;26:1289-95.
62. McGee C, O'Brien V, Van Nortwick S, Adams J, Van Heest A. First dorsal interosseous muscle contraction results in radiographic reduction of healthy thumb carpometacarpal joint. *J Hand Ther* 2015;28:375-80; quiz 381.

63. Mobargha N, Esplugas M, Garcia-Elias M, Lluch A, Megerle K, Hagert E. The effect of individual isometric muscle loading on the alignment of the base of the thumb metacarpal: a cadaveric study. *J Hand Surg Eur* 2016;41:374-9.
64. Cooney WP, An KN, Daube JR, Askew LJ. Electromyographic analysis of the thumb: a study of isometric forces in pinch and grasp. *J Hand Surg* 1985;10:202-10
65. Kerkhof FD, Deleu G, D'Agostino P, Vereecke EE. Subject-specific thumb muscle activity during functional tasks of daily life. *J Electromyogr Kinesiol* 2016;30:131-6.
66. Srinivasan H, Landsmeer JM. Internal stabilization in the thumb. *J Hand Surg Am* 1982;7:371-5.
67. Goubau JF, Benis S, Van Hoonacker P, Berghs B, Kerckhove D, Patonay L. Vascularization of the trapeziometacarpal joint and its clinical importance: anatomical study. *Chir Main* 2012;31:57-61.
68. Messina A. [Vascularized surgical rotation of a bi-articular trapezoid-trapeziometacarpal complex for the treatment of severe rhizarthrosis of the thumb]. *Chir Main* 2000;19:134-40.
69. Loréa P, Dury M, Marin Braun F, Dekkaï T, De Mey A, Foucher G. [Trapeziometacarpal denervation. Description of surgical technique and preliminary results from a prospective series of 14 cases]. *Chir Main* 2002;21:209-17.
70. Loréa P, Berthe JV, De Mey A, Coessens BC, Rooze M, Foucher G. [Thenar branch of the median nerve and innervation of the trapeziometacarpal joint]. *Chir Main* 2001;20:257-62.
71. Loréa DP, Berthe JV, De Mey A, Coessens BC, Rooze M, Foucher G. The nerve supply of the trapeziometacarpal joint. *J Hand Surg Br* 2002;27:232-7.
72. Poupon M, Duteille F, Cassagnau E, Leborgne J, Pannier M. [Anatomical study of the nerve supply of the trapeziometacarpal joint. Fifteen dissections]. *Rev Chir Orthop Reparatrice Appar Mot* 2004;90:346-52.

73. Miki RA, Kam CC, Gennis ER, Barkin JA, Riel RU, Robinson PG, Owens PW. Ulnar nerve component to innervation of thumb carpometacarpal joint. *Iowa Orthop J* 2011;31:225-30.
74. Loréa PD. First carpometacarpal joint denervation: anatomy and surgical technique. *Tech Hand Up Extrem Surg* 2003;7:26-31.
75. Espinosa Gutiérrez A, Trujillo Millán A, Ramírez Lozano G, Romo Rodríguez R, Zárate Ramírez G. [Arthroscopy of the trapeziometacarpal joint: anatomical study on cadavers]. *Acta Ortop Mex* 2008;22:402-4.
76. Napier JR. The form and function of the carpo-metacarpal joint of the thumb. *J Anat* 1955;89:362-9.
77. Dourthe B, D'Agostino P, Stockmans F, Kerkhof F, Vereecke E. In vivo contact biomechanics in the trapeziometacarpal joint using finite deformation biphasic theory and mathematical modeling. *Med Eng Phys*. 2016;38:108-14.
78. Momose T, Nakatsuchi Y, Saitoh S. Contact area of the trapeziometacarpal joint. *J Hand Surg Am* 1999;24:491-5.
79. Ateshian GA, Ark JW, Rosenwasser MP, Pawluk RJ, Soslowsky LJ, Mow VC. Contact areas in the thumb carpometacarpal joint. *J Orthop Res* 1995;13:450-8.
80. Halilaj E, Rainbow MJ, Got C, Schwartz JB, Moore DC, Weiss AP, Ladd AL, Crisco JJ. In vivo kinematics of the thumb carpometacarpal joint during three isometric functional tasks. *Clin Orthop Relat Res* 2014;472:1114-22.
81. Cooney WP 3rd, Chao EYS. Biomechanical analysis of static forces in the thumb during hand function. *J Bone Joint Surg Am* 1977;59:27-36.
82. Zancolli EA, Zaidenberg C, Zancolli E Jr. Biomechanics of the trapeziometacarpal joint. *Clin Orthop Relat Res* 1987;220:14-26.
83. Chèze L, Doriot N, Eckert M, Rumelhart C, Comtet JJ. [In vivo cinematic study of the trapeziometacarpal joint]. *Chir Main* 2001;20:23-30.

84. Crisco JJ, Halilaj E, Moore DC, Patel T, Weiss AP, Ladd AL. In vivo kinematics of the trapeziometacarpal joint during thumb extension-flexion and abduction-adduction. J Hand Surg Am 2015;40:289-96.
85. Halilaj E, Moore DC, Patel TK, Laidlaw DH, Ladd AL, Weiss AP, Crisco JJ. Thumb carpometacarpal joint congruence during functional tasks and thumb range-of-motion activities. Conf Proc IEEE Eng Med Biol Soc 2014;2014:4354-7.
86. Schneider MT, Zhang J, Crisco JJ, Weiss AP, Ladd AL, Nielsen P, Besier T. Men and women have similarly shaped carpometacarpal joint bones. J Biomech 2015 18;48:3420-6.
87. Ateshian GA, Rosenwasser MP, Mow VC. Curvature characteristics and congruence of the thumb carpometacarpal joint: differences between female and male joints. J Biomech 1992;25:591-607.
88. Halilaj E, Moore DC, Laidlaw DH, Got CJ, Weiss AP, Ladd AL, Crisco JJ. The morphology of the thumb carpometacarpal joint does not differ between men and women, but changes with aging and early osteoarthritis. J Biomech 2014 22;47:2709-14.
89. Kihara H. [Anatomical study of the normal and degenerative articular surfaces on the first carpometacarpal joint]. Nihon Seikeigeka Gakkai Zasshi 1992;66:228-39.
90. Wolf JM, Oren TW, Ferguson B, Williams A, Petersen B. The carpometacarpal stress view radiograph in the evaluation of trapeziometacarpal joint laxity. J Hand Surg Am. 2009;34:1402-6.
91. Jónsson H, Elíasson GJ, Jónsson A, Eiríksdóttir G, Sigurdsson S, Aspelund T, Harris TB, Gudnason V. High hand joint mobility is associated with radiological CMC1 osteoarthritis: the AGES-Reykjavik study. Osteoarthritis Cartilage 2009;17:592-5.
92. Wolf JM, Schreier S, Tomsick S, Williams A, Petersen B. Radiographic laxity of the trapeziometacarpal joint is correlated with generalized joint hypermobility. J Hand Surg Am 2011;36:1165-9.

93. Kraus VB, Li YJ, Martin ER, Jordan JM, Renner JB, Doherty M, Wilson AG, Moskowitz R, Hochberg M, Loeser R, Hooper M, Sundseth S. Articular hypermobility is a protective factor for hand osteoarthritis. *Arthritis Rheum* 2004;50:2178-83.
94. Pellegrini VD Jr, Olcott CW, Hollenberg G. Contact patterns in the trapeziometacarpal joint: the role of the palmar beak ligament. *J Hand Surg Am* 1993;18:238-44.
95. Kwok WY, Kloppenburg M, Marshall M, Nicholls E, Rosendaal FR, Peat G. The prevalence of erosive osteoarthritis in carpometacarpal joints and its clinical burden in symptomatic community-dwelling adults. *Osteoarthritis Cartilage* 2014;22:756-63.
96. Moriatis Wolf J, Turkiewicz A, Atroshi I, Englund M. Prevalence of doctor-diagnosed thumb carpometacarpal joint osteoarthritis: an analysis of Swedish health care. *Arthritis Care Res (Hoboken)* 2014;66:961-5.
97. Armstrong AL, Hunter JB, Davis TR. The prevalence of degenerative arthritis of the base of the thumb in post-menopausal women. *J Hand Surg Br* 1994;19:340-1.
98. Brown GD 3rd, Roh MS, Strauch RJ, Rosenwasser MP, Ateshian GA, Mow VC. Radiography and visual pathology of the osteoarthritic scaphotrapeziotrapezoid joint, and its relationship to trapeziometacarpal osteoarthritis. *J Hand Surg Am* 2003;28:739-43.
99. Scordino LE, Bernstein J, Nakashian M, McIntosh M, Cote MP, Rodner CM, Wolf JM. Radiographic prevalence of scaphotrapeziotrapezoid osteoarthrosis. *J Hand Surg Am* 2014;39:1677-82.
100. Maes-Clavier C, Bellemère P, Gabrion A, David E, Rotari V, Havet E. Anatomical study of the ligamentous attachments and articular surfaces of the trapeziometacarpal joint. Consequences on surgical management of its osteoarthrosis. *Chir Main* 2014;33:118-23.

101. Koff MF, Ugwonalie OF, Strauch RJ, Rosenwasser MP, Ateshian GA, Mow VC. Sequential wear patterns of the articular cartilage of the thumb carpometacarpal joint in osteoarthritis. *J Hand Surg Am* 2003;28:597-604.
102. Shi Q, Hashizume H, Inoue H, Miyake T, Nagayama N. Finite element analysis of pathogenesis of osteoarthritis in the first carpometacarpal joint. *Acta Med Okayama* 1995;49:43-51.
103. Momose T. [Cartilage degeneration and measurement of the contact area of the trapeziometacarpal joint: morphological observation]. *Nihon Seikeigeka Gakkai Zasshi* 1994;68:426-34.
104. D'Agostino P, Dourthe B, Kerkhof F, van Lenthe GH, Stockmans F, Vereecke EE. In vivo biomechanical behavior of the trapeziometacarpal joint in healthy and osteoarthritic subjects. *Clin Biomech (Bristol, Avon)* 2017;49:119-27.
105. Xu L, Strauch RJ, Ateshian GA, Pawluk RJ, Mow VC, Rosenwasser MP. Topography of the osteoarthritic thumb carpometacarpal joint and its variations with regard to gender, age, site, and osteoarthritic stage. *J Hand Surg Am* 1998;23:454-64.
106. Nufer P, Goldhahn J, Kohler T, Kuhn V, Müller R, Herren DB. Microstructural adaptation in trapezium bone due to subluxation of the thumb. *J Orthop Res* 2008;26:208-16.
107. Lee AT, Williams AA, Lee J, Cheng R, Lindsey DP, Ladd AL. Trapezium trabecular morphology in carpometacarpal arthritis. *J Hand Surg Am* 2013;38:309-15.
108. Kovler M, Lundon K, McKee N, Agur A. The human first carpometacarpal joint: osteoarthritic degeneration and 3-dimensional modeling. *J Hand Ther* 2004;17:393-400.
109. Doerschuk SH, Hicks DG, Chinchilli VM, Pellegrini VD Jr. Histopathology of the palmar beak ligament in trapeziometacarpal osteoarthritis. *J Hand Surg Am* 1999;24:496-504.

110. Pellegrini VD Jr. Comparative pathoanatomy of the Asian and Caucasian trapeziometacarpal joint. *Ann Acad Med Singapore* 1995;24(4 Suppl):21-5.
111. Omokawa S, Ryu J, Tang JB, Han J, Kish VL. Trapeziometacarpal joint instability affects the moment arms of thumb motor tendons. *Clin Orthop Relat Res* 2000;372:262-71.
112. Miura T, Ohe T, Masuko T. Comparative in vivo kinematic analysis of normal and osteoarthritic trapeziometacarpal joints. *J Hand Surg Am* 2004;29:252-7.
113. D'Agostino P, Dourthe B, Kerkhof F, Vereecke EE, Stockmans F. Impact of osteoarthritis and total joint arthroplasty on the kinematics of the trapeziometacarpal joint. *J Hand Surg Am* 2018;43:382.e1-382.e10.
114. Schöneberger M, Koebke J. [Rhizarthrosis and thenar muscles. A clinico-anatomic study]. *Handchir Mikrochir Plast Chir* 1989;21:182-8.
115. Pellegrini VD Jr, Smith RL, Ku CW. Pathobiology of articular cartilage in trapeziometacarpal osteoarthritis. II. Surface ultrastructure by scanning electron microscopy. *J Hand Surg Am* 1994;19:79-85.
116. Rivers PA, Rosenwasser MP, Mow VC, Pawluk RJ, Strauch RJ, Sugalski MT, Ateshian GA. Osteoarthritic changes in the biochemical composition of thumb carpometacarpal joint cartilage and correlation with biomechanical properties. *J Hand Surg Am* 2000;25:889-98.
117. Clifton KB, Rodner C, Wolf JM. Detection of relaxin receptor in the dorsoradial ligament, synovium, and articular cartilage of the trapeziometacarpal joint. *J Orthop Res* 2014;32:1061-7.
118. Gehrmann SV, Tang J, Li ZM, Goitz RJ, Windolf J, Kaufmann RA. Motion deficit of the thumb in CMC joint arthritis. *J Hand Surg Am* 2010;35:1449-53.
119. Wu JZ, Li ZM, Cutlip RG, An KN. A simulating analysis of the effects of increased joint stiffness on muscle loading in a thumb. *Biomed Eng Online* 2009;8:41.

120. McQuillan TJ, Kenney D, Crisco JJ, Weiss AP, Ladd AL. Weaker functional pinch strength is associated with early thumb carpometacarpal osteoarthritis. Clin Orthop Relat Res 2016;474:557-61.
121. Coughlan MJ, Bourdillon A, Crisco JJ, Kenney D, Weiss AP, Ladd AL. Reduction in cylindrical grasp strength is associated with early thumb carpometacarpal osteoarthritis. Clin Orthop Relat Res 2017;475:522-8.
122. Villafañe JH, Valdes K. Combined thumb abduction and index finger extension strength: a comparison of older adults with and without thumb carpometacarpal osteoarthritis. J Manipulative Physiol Ther 2013;36:238-44.
123. Cantero-Téllez R, Martín-Valero R, Cuesta-Vargas A. Effect of muscle strength and pain on hand function in patients with trapeziometacarpal osteoarthritis. A cross-sectional study. Reumatol Clin 2015;11:340-4.
124. Dominick KL, Jordan JM, Renner JB, Kraus VB. Relationship of radiographic and clinical variables to pinch and grip strength among individuals with osteoarthritis. Arthritis Rheum 2005;52:1424-30.
125. Halilaj E, Moore DC, Patel TK, Ladd AL, Weiss AP, Crisco JJ. Early osteoarthritis of the trapeziometacarpal joint is not associated with joint instability during typical isometric loading. J Orthop Res 2015;33:1639-45.
126. Lovati AB, Colombini A, Recordati C, Ceriani C, Zagra L, Berzero G, Moretti M. Chondrogenic capability of osteoarthritic chondrocytes from the trapeziometacarpal and hip joints. Cell Tissue Bank 2016;17:171-7.
127. Ledoux P. M1/M2 Ratio for radiological follow-up of trapeziometacarpal surgery. Hand Surg Rehabil 2017 ;36:146-7.
128. Moulton MJ, Parentis MA, Kelly MJ, Jacobs C, Naidu SH, Pellegrini VD Jr. Influence of metacarpophalangeal joint position on basal joint-loading in the thumb. J Bone Joint Surg Am 2001;83:709-16.

129. Koff MF, Zhao KD, Mierisch CM, Chen MY, An KN, Cooney WP 3rd. Joint kinematics after thumb carpometacarpal joint reconstruction: an in vitro comparison of various constructs. *J Hand Surg Am* 2007;32:688-96.
130. Domalain MF, Seitz WH, Evans PJ, Li ZM. Biomechanical effect of increasing or decreasing degrees of freedom for surgery of trapeziometacarpal joint arthritis: a simulation study. *J Orthop Res* 2011;29:1675-81.
131. Duerinckx J, Caekebeke P. Trapezium anatomy as a radiographic reference for optimal cup orientation in total trapeziometacarpal joint arthroplasty. *J Hand Surg Eur* 2016;41:939-43.
132. Oberlin C. [Comparative anatomy of the hand]. *Chir Main* 2006;25:111-8.
133. Marzke MW, Tocheri MW, Steinberg B, Femiani JD, Reece SP, Linscheid RL, Orr CM, Marzke RF. Comparative 3D quantitative analyses of trapeziometacarpal joint surface curvatures among living catarrhines and fossil hominins. *Am J Phys Anthropol* 2010;141:38-51.
134. van Leeuwen T, Vanneste M, Kerkhof F, D'Agostino P, Vanhoof M, Stevens J, van Lenthe GH, Vereeck EE. Mobility and structural constraints of the bonobo trapeziometacarpal joint. *Biol J Linn Soc Lond* 2019;127:681-93.
135. Marzke MW, Marzke RF, Linscheid RL, Smutz P, Steinberg B, Reece S, An KN. Chimpanzee thumb muscle cross sections, moment arms and potential torques, and comparisons with humans. *Am J Phys Anthropol* 1999;110:163-78.
136. Marzke MW. Evolutionary development of the human thumb. *Hand Clin* 1992;8:1-8.

Figure legends

Fig. 1. Distal (A) and palmar (B) view of the trapeziometacarpal after the first metacarpal has been removed. The axes around which abduction-adduction (K-wire A) and antepulsion-retropulsion (K-wire B, entering the palmar beak of trapezium) occur are not completely orthogonal, are not secant and are not located in the reference planes (from Zancolli and Cozzi, Atlas of surgical anatomy of the hand. Churchill Livingstone 1992). *H*: hook of hamate; *L*: anterior horn of lunate; *P*: pisiform; *S*: scaphoid; *T*: trapezium.

Fig. 2. Anatomy of trapezium. Palmar (A), dorsal (B), medial (C) and distal (D) views. *FCR*: flexor carpi radialis; *M*: articular surface for 1st metacarpal; *S*: articular surface for scaphoid; *T*: articular surface for trapezoid

Fig. 3. Anterior (A) and lateral (B) views of the trapeziometacarpal joint. *APL*: abductor pollicis longus ; *dAOL*: deep anterior oblique ligament (visible through a window in the *sAOL*); *DIML*: dorsal intermetacarpal ligament ; *DRL*: dorsoradial ligament ; *FCR*: flexor carpi radialis ; *IML*: intermetacarpal ligament ; *POL*: posterior oblique ligament ; *sAOL*: superficial anterior oblique ligament ; *UCL*: ulnar collateral ligament.

Fig. 4. The distally inserting tendons of the abductor pollicis longus (lateral view, left hand). This dissection shows three tendons ending on the 1) muscle body of the abductor pollicis brevis, 2) the trapeziometacarpal capsule, 3) the first metacarpal base.

Fig. 5. To generate a 1 kg pinch grip, the trapeziometacarpal joint supports 10 kg of load (from Cooney & Chao [76]).

Figure 1A

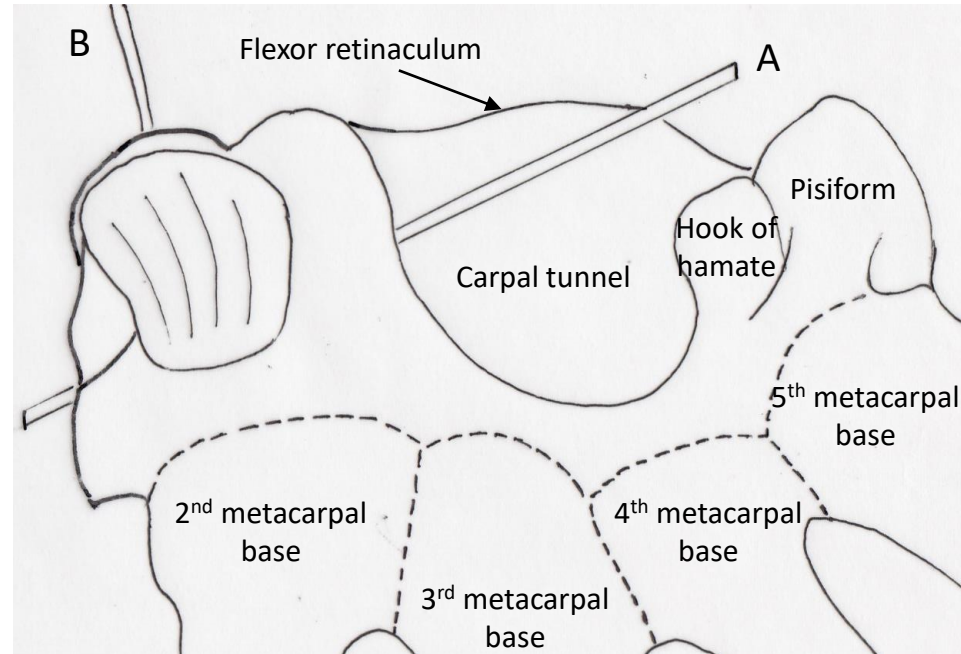


Figure 1B

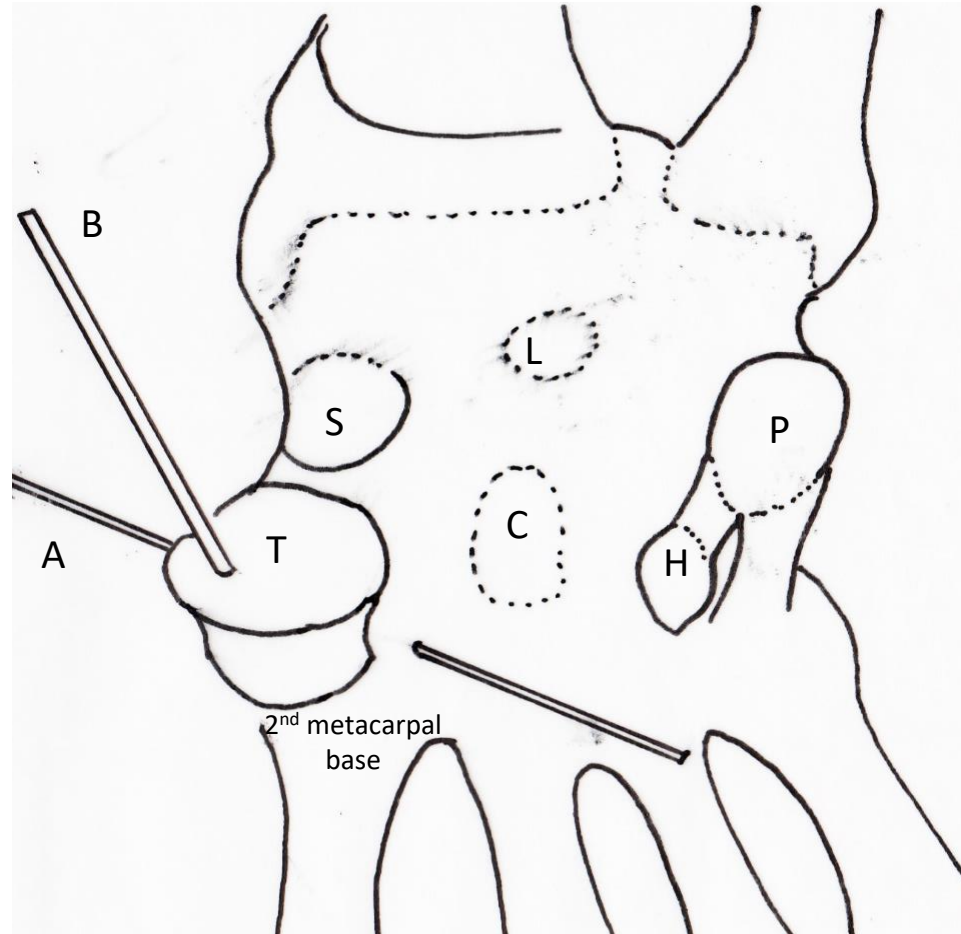


Figure 2A

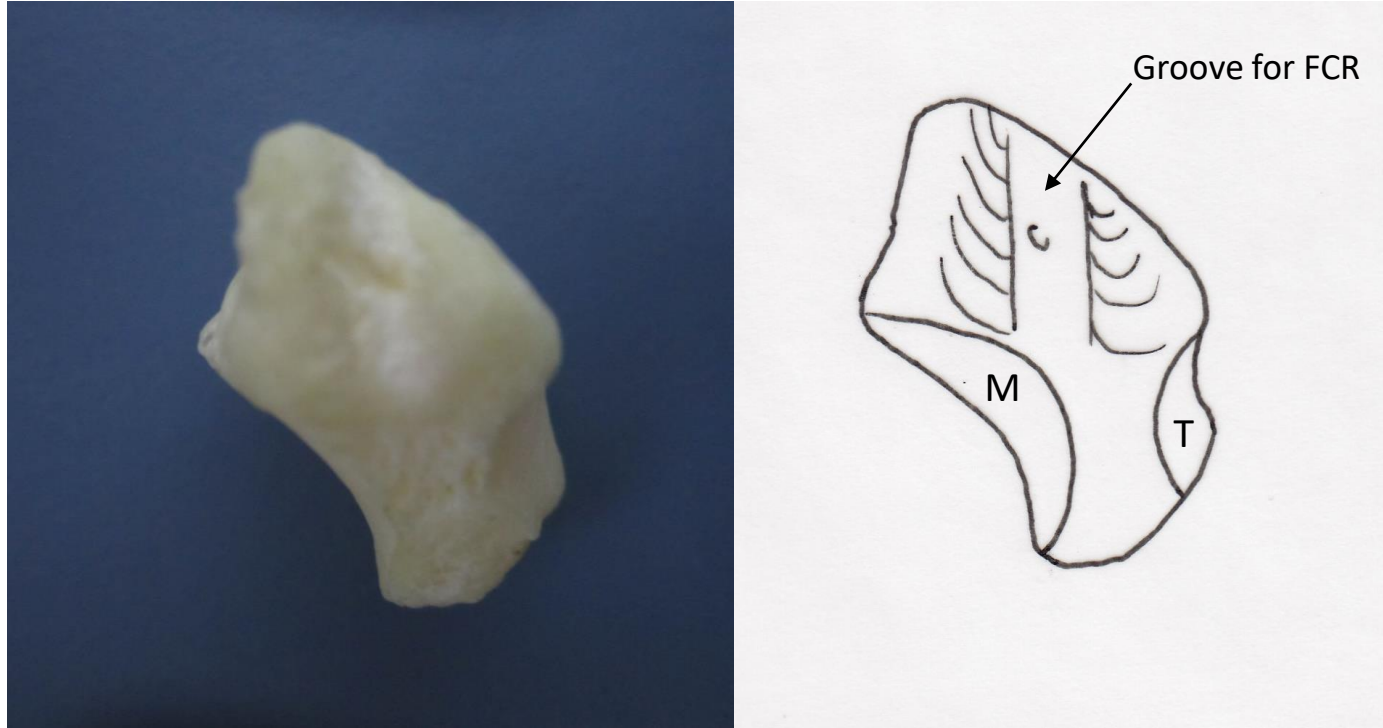


Figure 2B

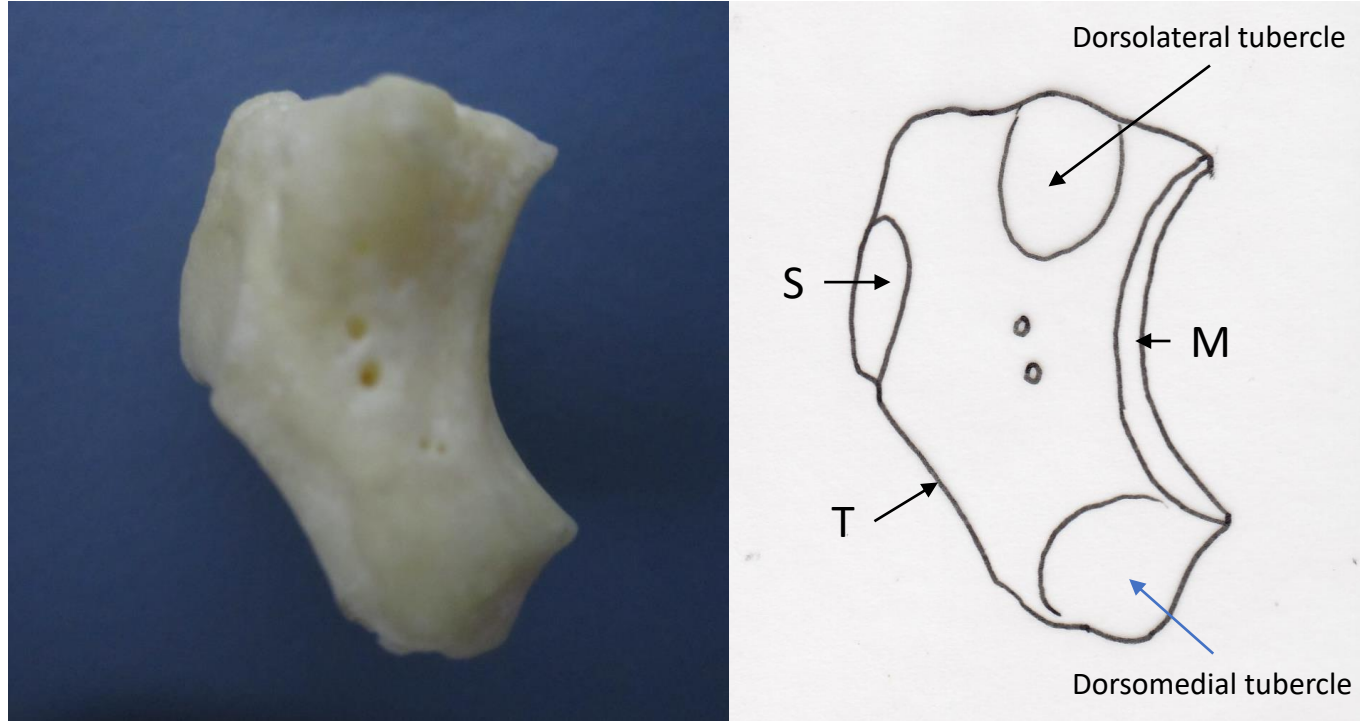


Figure 2C

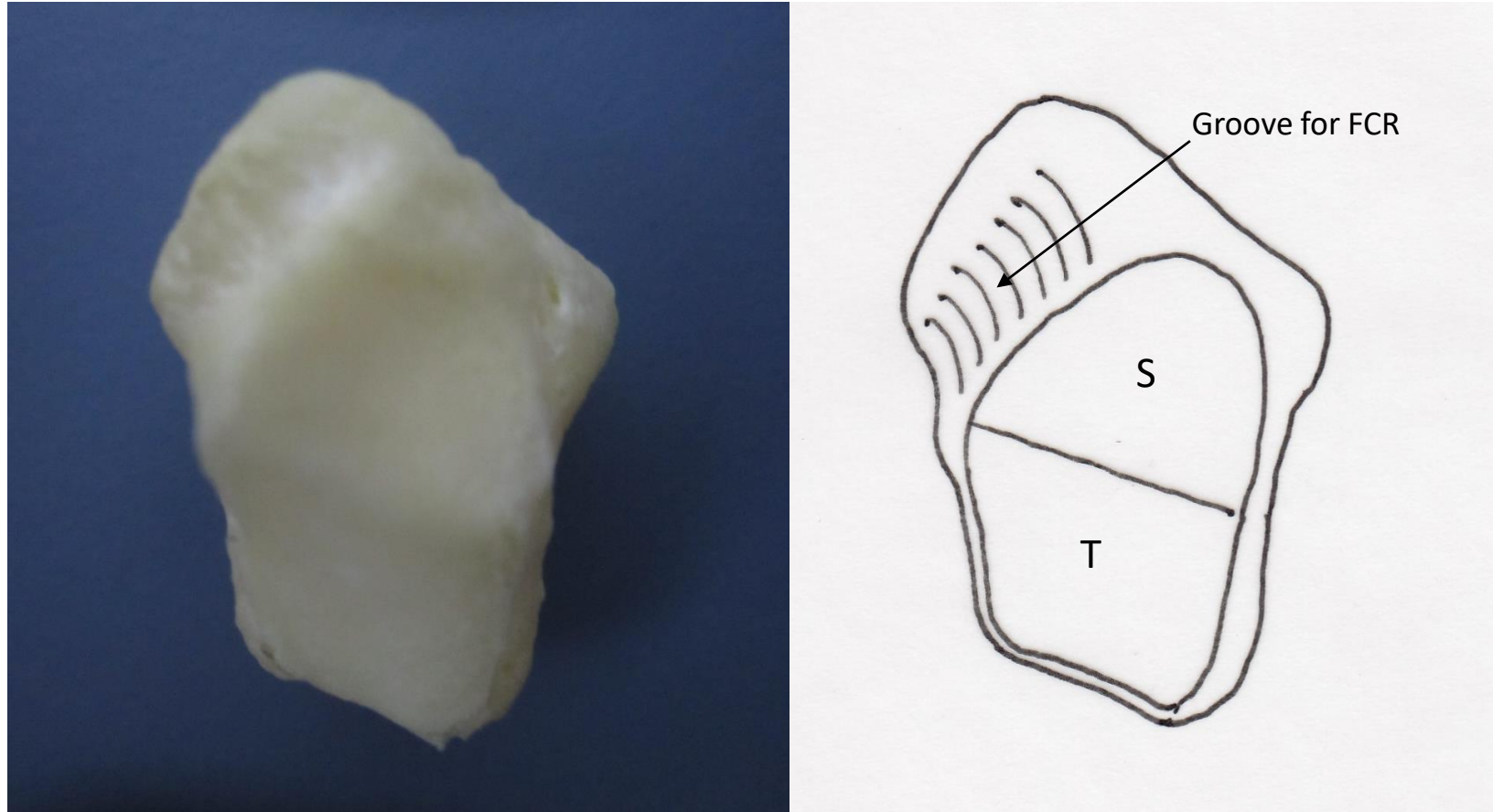


Figure 2D

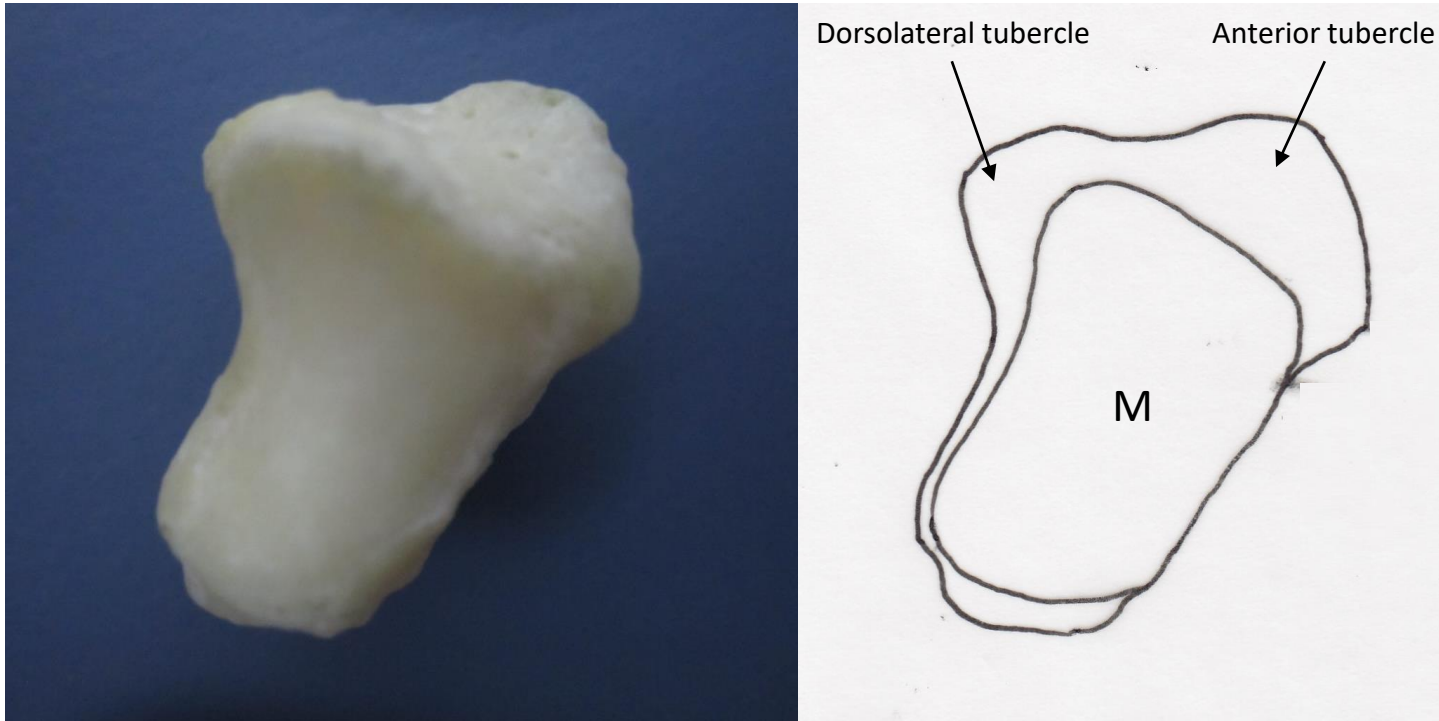


Figure 3A

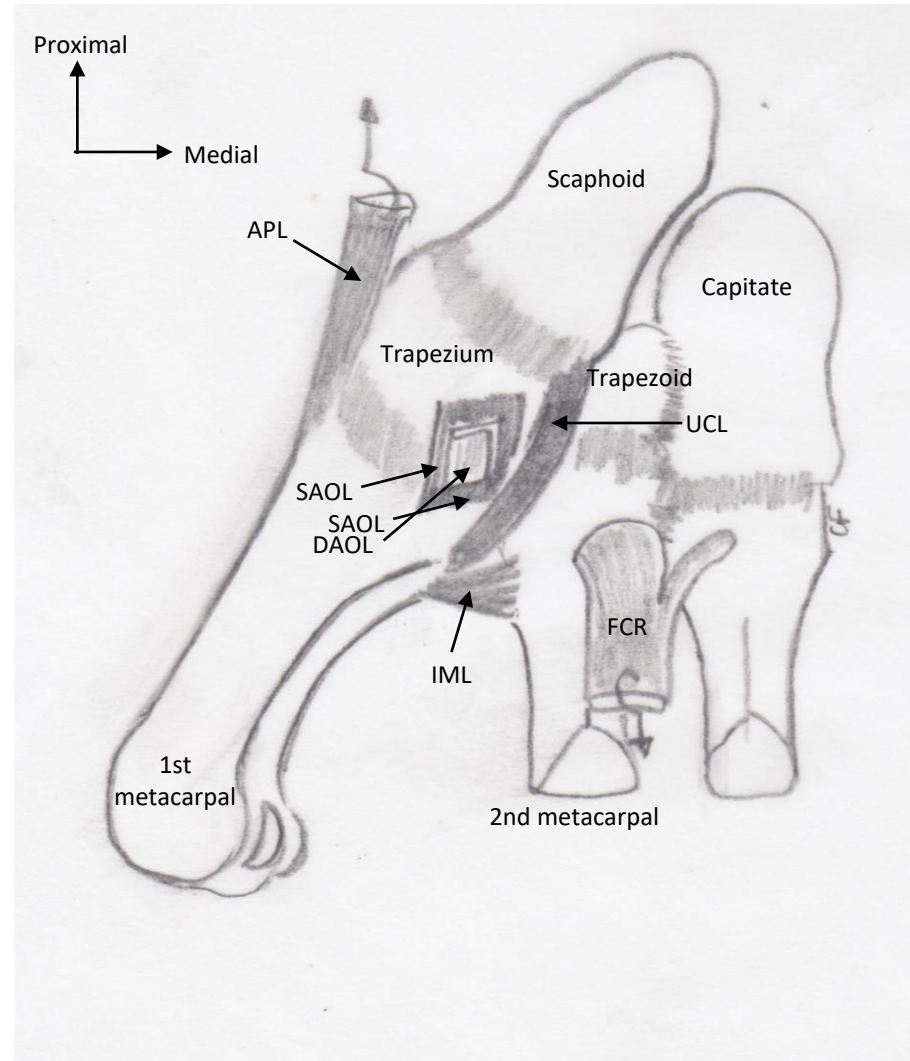


Figure 3B

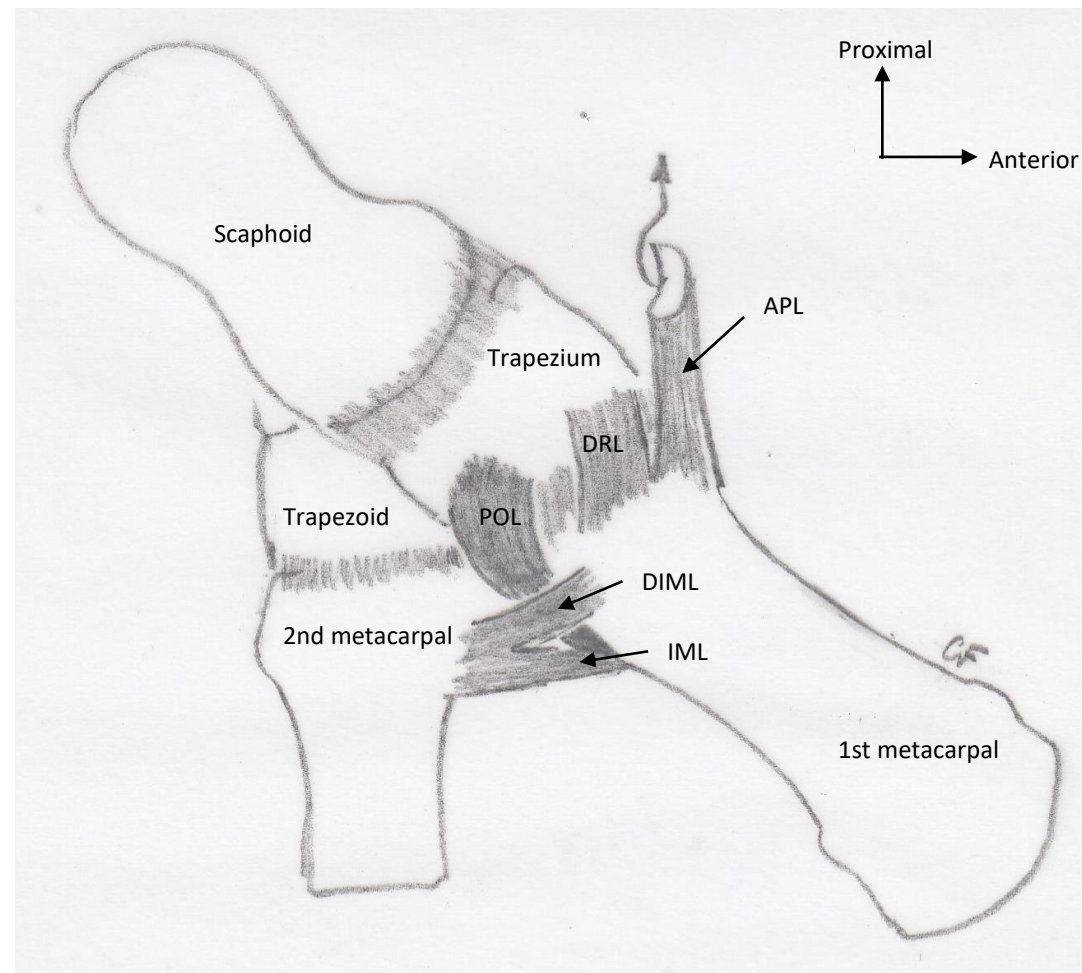


Figure 4

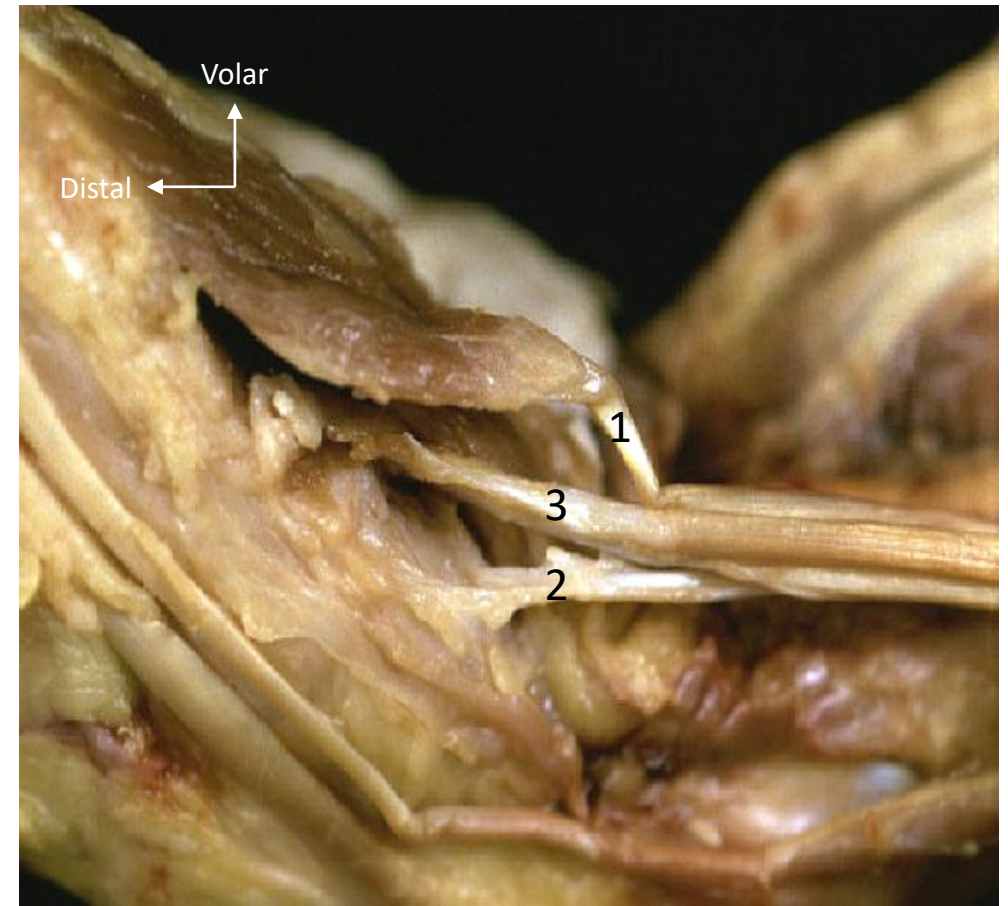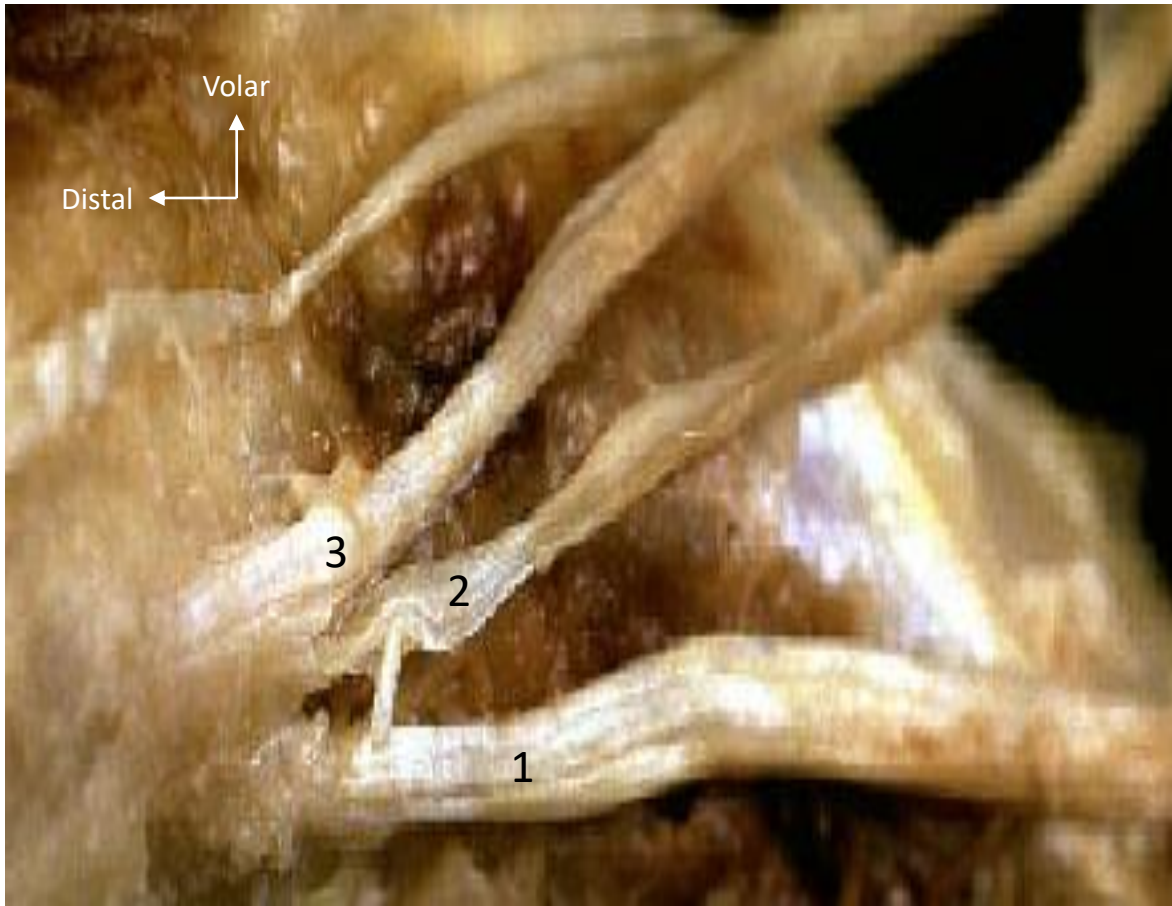


Figure 5

